



**Oncocyte**  
**Oncocytic Tumors / Neoplasm**  
**Oncocytic Metaplasia**

---

**Dr. R. G. Wiseman Pinto**

*Terms for Oncocytic*

*History*

*Oncocytic Cell*

*Organs*

*Tumors*

*Molecular biology*

Oncocyte

Also called as

Oxyphilic cell

Hurtle Cell

Oncocyte

Askanazy Cell

Preferred term today is Oncocyte

History

In 1931 Hamperl coined the term Oncocyte  
(Onkocyten )

Morphology of the cell

Abundant cytoplasm

Eosinophil

Granular

Packed with Mitochondria

Nucleus is central , hyperchromatic

Sometimes there is condensation of Mitochondria at the periphery of the cell , clear cell appearance

Normal

Elderly

Oncocytic metaplasia of ductal epithelium

Oncocytic metaplasia of acinar cells

Oncocytic Tumors / Neoplasm

Oncocytic change may be

Focal

Diffuse

Complete

Mitochondria  
Enigma of Metabolism  
Apoptosis  
Modulates immunity  
Regulates Nuclear stability

Tumoral Mitochondriopathy

Mitochondria may be functionally and structurally abnormal

ROS Transformation

Otto Warburg  
Warburg effect

Cytopathology  
Histopathology  
Molecular Biology

Benign  
Malignant  
Morphology  
Metabolism

Mitochondria also involved in.  
Aging  
Neurodegeneration

Systemic Disease

Multiorgan  
Multidisciplinary

Cytopathology  
Histopathology  
Endocrine Pathology  
Molecular biology

Oncocytes are seen in the following Organs

Salivary Gland  
Thyroid  
Kidney  
Pancreas  
Adrenal  
Familial and Syndromic

SMT  
Somatic Mutation Theory

Targeted therapy

BRAF inhibitors in Melanoma

EGFR inhibitors in lung Adenocarcinoma

Warburg effect

Aerobic Metabolism

In cancer

Proliferative signals

Apoptosis resistance

Angiogenesis

Metabolism

Genomic instability

Mutation in Mitochondrial DNA genes

And

Nuclear DNA genes encoding Mitochondrial proteins.

Oncocytic Tumors in Salivary Gland

1 Primary Oncocytic Salivary Gland Tumor

2 Oncocytic subtypes of Non Oncocytic Salivary Gland Tumors

Oncocytoma

Warthins Tumor

Mucoepidermoid Carcinoma

Salivary Duct Carcinoma

Multimodular Oncocytic Hyperplasia

(Nodular Oncocytic Hyperplasia)

Ancillary

AR in Salivary duct Carcinoma

NGS. FISH

MAML2 gene change in Mucoepidermoid Carcinoma

PILAG / HMGA2 in Pleomorphic Adenoma

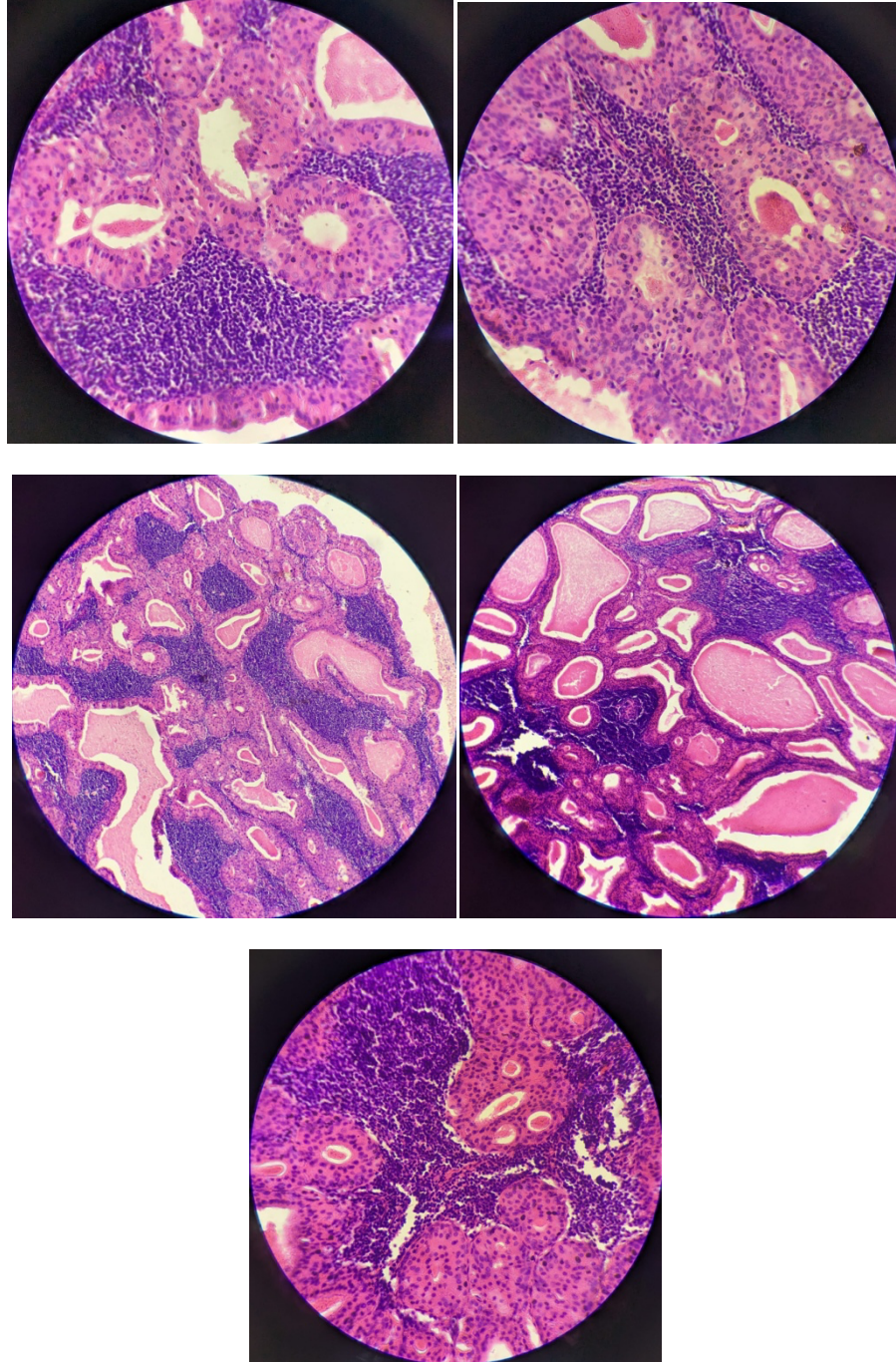
### **Warthins Tumor of the Right Parotid Gland**

62 y old male

Superficial Parotidectomy

Done

in GMC in 2024



---

Dr. R.G. Wiseman Pinto is a Professor of Pathology, former Head of Department at Goa Medical College, former Dean of Goa University, and the current President of the Asian Society of Cytopathology (SACH)