

Hairy Cell Leukemia
(Classic Hairy Cell Leukemia)
(HCL)
(Leukemic Reticuloendotheliosis)

Edited BY:

Dr R.G. Wiseman Pinto
Prof and Head Pathology
Ex Dean Goa University
Ex Executive Council Goa University
President Asian Society of Cytopathology
Chairman International Affairs IAC

Names of Contributors

1. *Dr.R.G.W.Pinto - Goa*
2. *Dr.Sumeet Gujral - TMH, Mumbai*
3. *Dr.Nikita Oza - Mumbai*
4. *Dr.Mahadeva Swamy - Goa*

Hairy Cell Leukemia

By : Dr. R. G. W. Pinto

Hairy Cell Leukemia

HCL

Rare

2 % of Leukemia

B Cell neoplasm

Occurs in middle age and old age

Median is 55 y

M:F 5:1

Chronic

Indolent

Lymphoproliferative

Affects the Bone Marrow .Spleen and sometimes the liver

Old age

Pancytopenia

Splenomegaly

On PS Hairy cells

Pathogenesis

90 percent have activating point mutation in the gene

BRAFV600E gene

This gene encodes Serine /Threonine kinase

HCL has a picturesque name

Leukemia cells have hair like projections on the surface

DD

1 Splenic B Cell Lymphoma

2 Splenic L with villous lymphocytes

3 Splenic Marginal Zone L

4 Diffuse Red pulp L

Molecular/ Cytogenetics

BRAFV600E Mutation

Histone. Methyl transferable Mutation

Deletion of chromosome 7q and 13q

Gains of chromosome 5

Electron Microscopy

Cyto inclusions

Ribosomes - Lamellar complex (RLC)

IHC

Positive Stains / Markers

B Cells CD19 .CD20. .CD 22. .CD79a .PAX5

Annexin A1

TRAP Tartaric acid resistant Acid Phosphatase

Cyclin D1

BRAFV600E

TIA1

CD11c

CD123

CD 103 Cell adhesion

CD 305 LAIR

CD25

Negative Stains IHC

CD5. .CD23. CD10. and Bcl 6

Genetics

NGS

BRAFV600E Mutation

In more than 95 percent

Pancytopenia

Monocytopenia

More common in whites

Less in Africans .Asians .Arabs

Risk factors

Farming

Insecticides

Petroleum

Diesel

Ionizing Radiations

Smoking has a protective effect

Investigations

CBC

DC
BM
Flow Cytometry
Immunophenotype
IHC
Molecular
B2 Microglobulin

Flow
CD45 . CD20 . CD22 . CD11c . CD103 . CD123 . CD305 (LAIR)

Spleen
Massive Splenomegaly
More than 150 gm.
No modularity
Red pulp is infiltrated
Lakes . pools of blood.
Lined by Hairy cells
Beefy Red app
Obliteration of white pulp.

Liver
Portal tracts are involved

Bone Marrow
Dry tap because of
Fibrosis
Reticulin

BM Trepine
Involvement is patchy . subtle.
Intestinal . Diffuse Solid
10 percent is aplastic Anemia
Reticulin stain
" Honeycomb "
" Halo "
" Fried egg app "

Reduction in myeloid , erythroid and megakaryocytic series.
IHC

Diagnosis
Old age

Splenomegaly
Pancytopenia
PS Hairy cells
TRAP
BRAFV600E Mutation

Clinical

Fatigue Weakness. Pallor
Easy bruising
Inf
Fever
Splenomegaly
Hepatomegaly sometimes
No peripheral LNs
Pancytopenia
Inf one third
TB Atypical Myco

Course

Indolent
Chronic
Prognosis
Excellent
5 year survival is 90 percent
Chemo
BRAF inhibitors

Poor prognosis if

1. Massive Splenomegaly
2. Leucocytosis More than 10×10^9 per l
3. Hairy cells More than $.5 \times 10^9$. per l
4. B2 microglobulin elevated
5. Unstated IGHV
6. IGHV 34 positive Ig variable Heavy chain gene rearrangement
7. CD 38 expression

Size of the Hairy cells

2 times the size of small lymphocyte
Nucleus round. Oval or reniform
Slightly eccentric
Bland

Hairy cells

Few cells to many

5 percent to 90 percent of WBCs

Neutropenia

Monocytopenia

Size of the Hairy cells

10 to 14 microns

15 to 25 microns

Cyto blue to pale blue

Hair like projections

Dry tap 30 to 50 percent of cases

Spindle cells

Reticulin encircles individual cells

Isolated Bone upper femur may be involved

LN

Interfollicular

Interferon s

0.25 percent of cases develop Abdominal LNs

HCL

As there is pancytopenia

To get a good yield of Hairy cells

Buffy coat

FNAC of spleen if the platelet count is above 1 lakh per cmm

The FNAC material can be used for

Diagnosis

IHC

TRAP

Molecular and Genetic analysis

Hairy Cell Leukemia

2 percent of all Leukemia cases

In North America and Western Europe

Annually 2000 new cases of HCL are seen

Old names

Histiocytic Leukemia

Malignant Reticulocytosis
Lymphoid Myelofibrosis

History

In 1958 Dr Bertha Bouroncle at Ohio State Univ In USA first described and named the disease as Leukemic Reticuloendotheliosis

In 1966 the term Hairy Cell Leukemia was and continues to be used

A Hairy Cell Leukemia Foundation set up in 2013

With Research and clinical trials on MD Andrrson Cancer Center Hoston Texas USA .NCI Bethesda .Ohio state university and Royal Marsden Hosp London.

There is a mutation in
BRAFV600E gene
Of Late Activated Memory B Cells

Disease is Clonal

RAS - RAF - MAPK signaling pathway is involved.

Hairy
Fluffy

Some pts may have
Autoimmune. Hemolytic Anemia
Autoimmune Thrombocytopenia

Infections due to
Immunosuppressive
Cytopenia
Myelosuppressive therapy

Median survival is 4 years without treatment

Complications
Second Malignancy
Due to immunosuppressive and Chemotherapy

Dr.Bertha Bouroncle et al described 26 patients in 1958 and termed the disease as Leukemic Reticuloendotheliosis

Immunoglobulin Gene Rearrangement

MRD

Minimal Residual Disease

Molecular

Askanazi Jews

Common

Whites

In 2016 in USA 1100 new cases were detected annually.

Hairy Cells have Integrin Receptors

These combine and react with VCAM 1 Vascular Adhesion Molecule.

This receptor is expressed in the spleen .BM .liver endothelial and on the splenic stroma

That is why these organs are involved. In HCL

Second malignancies in HCL

Skin Cancer

Prostate Cancers

GIT Cancers

NHL

Ovarian, Cervix ,Breast Cancers

Anti CD 20 antibody Rituximab

BRAF inhibitor

Vemurafenib

Splenectomy

Hematopoietic Stem Cell Transplant

Hairy Cell Leukemia

Studies

Blood Cancer 2020

279 cases Worldwide

Metaanalysis

Jerome Paillasa et al

Blood Cancer Journal 10 .62. 2020

30 year experience in a Multicentric study in Italy

Blood Cancer Journal 12 .109 .2022

Living Pagano et al

1991 - 2019

513 patients of Hairy Cell Leukemia

233 patients of HCL
Else met
Br J Hematology 145 .733 - 740

28 cases of HCL
JB.johnston et al
Europe pic.org
NCI Canada

Tata Memorial Hospital
Suneet Gujral et al
2009
4 year period
18 cases of HCL

AIIMS New Delhi
Mukul Aggarwal . Venkatesan Somasundaram et al
2002 - 2013
35 cases of HCL

2013 - 2023
20 cases of HCL

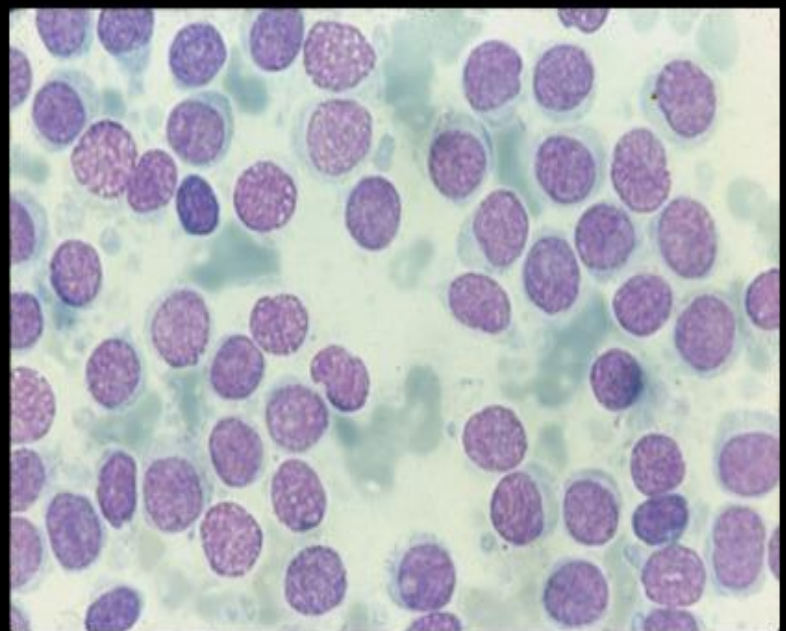
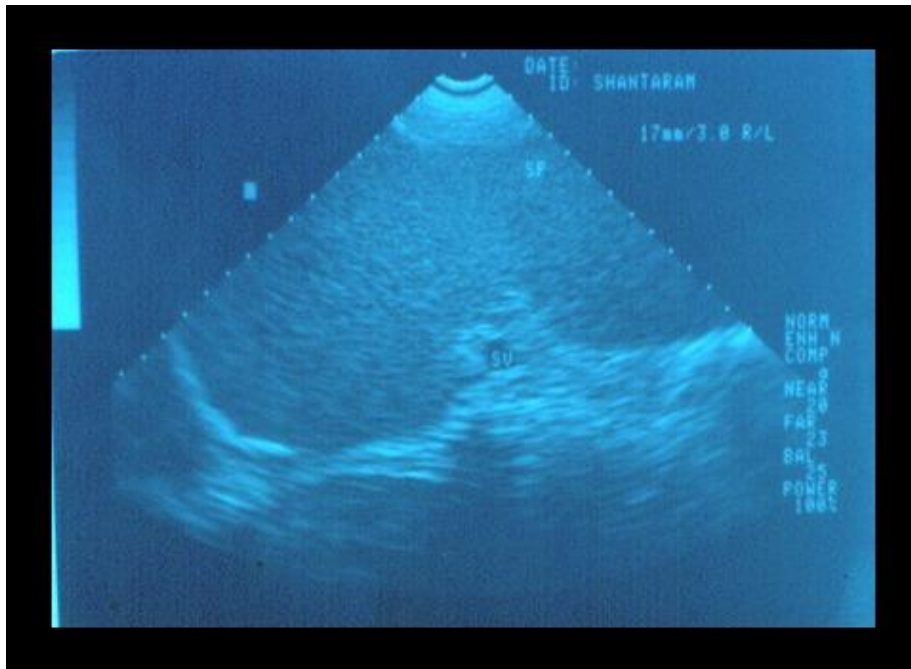
Gujarat Cancer and Research Institute Ahmedabad
K Patek .Rupali Shah et al
2009 - 2012
18 cases of HCL

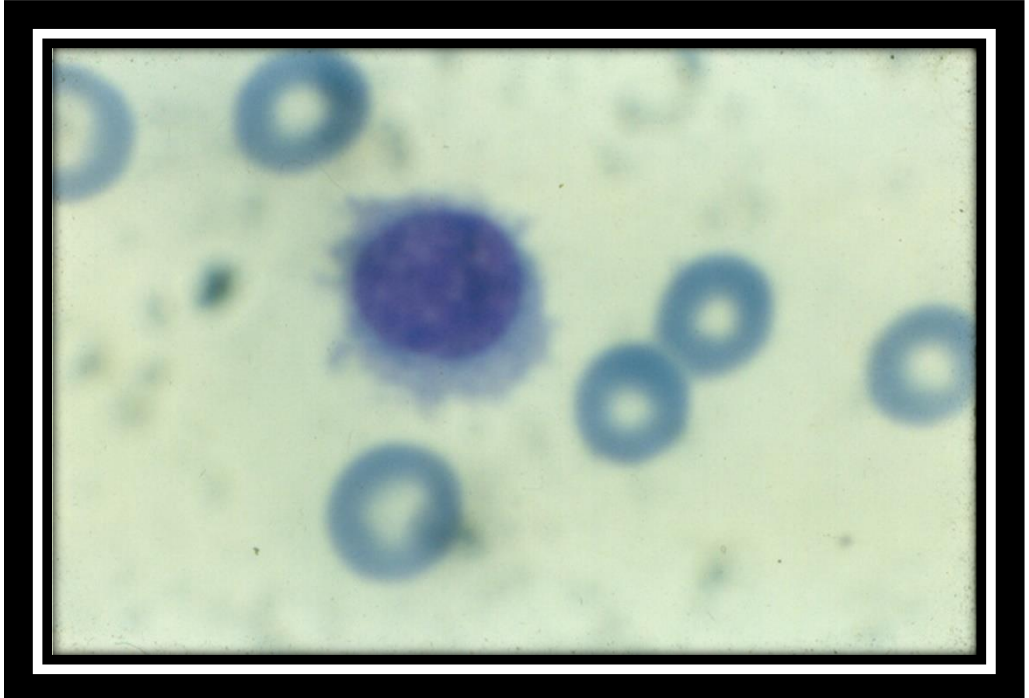
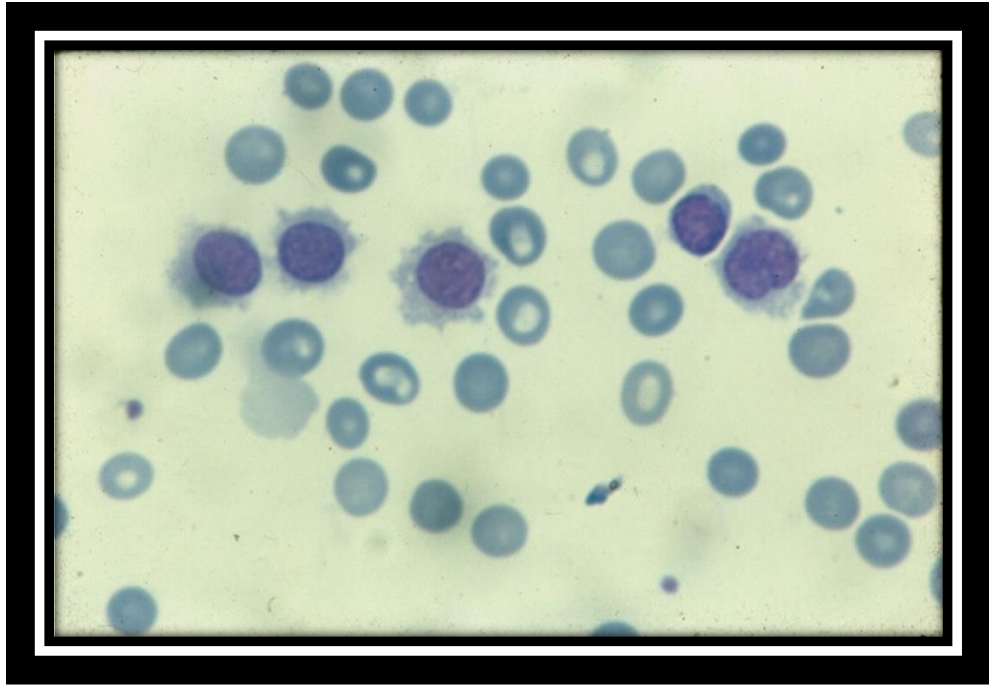
Kidwai Memorial Institute of Oncology
2016
10 cases of HCL

Goa
Dr RGW Pinto
Fine Needle Aspiration of the Spleen in Hairy Cell Leukemia
Acta Cytologica
1995 .39 .777 - 780

PGIMER Chandigarh
K.Medhi et al
2008 - 2012
21 cases of HCL

In Goa Medical College Between 2003 to 2023 there were 7 cases of HCL.





HAIRY CELL LEUKEMIA

Dr Mahadeva Swamy

Introduction:- Hairy cell leukemia (HCL) is a rare hematological malignancy that arises from late-activated post-germinal center memory B-cells. The hallmark of HCL is the presence of medium-sized mature lymphocytes with “hairy” projections in the bone marrow, spleen, and sometimes extramedullary tissues. Peripheral blood involvement is less common. HCL represents 2% of new leukemias and is more frequent in men than women, with a median age at diagnosis of approximately 52–63 in men and 51–59 in women.

Diagnosis:- Common clinical findings at the time of diagnosis include pancytopenia, splenomegaly, and increased risk of infection; monocytopenia is nearly universal, and the mechanism of this remains elusive. Extramedullary involvement such as lymphadenopathy and bone involvement are uncommon at diagnosis but may be seen more frequently in the relapsed setting. Diagnosis of HCL is suggested by the clinical presentation of the patient and confirmed by laboratory findings including a complete blood count with peripheral blood smear review, a bone marrow aspiration, and trephine biopsy with the assessment of bone marrow morphology, immunohistochemistry, flow cytometry, and testing for the identification of the BRAF V600E mutation. HCL has distinct immunophenotype comprised of CD11c, CD103, CD123, and CD25 according to the diagnostic score proposed by Matutes et al. HCL cells additionally co-express CD19, CD20, CD22, and CD200 and are classically negative for CD5, CD10, CD23, and CD27.

Treatment:- The majority of patients will require treatment at the time of diagnosis as a result of peripheral blood cytopenias or splenomegaly. According to consensus guidelines, initiation of treatment is guided by the presence of at least one of the following: hemoglobin < 11 g/dL, platelets < 100,000/ μ L, or absolute neutrophil count (ANC) < 1000/ μ L.

Initial therapy:- HCL cannot be cured with currently available therapies, highly effective treatments are available for eligible patients. The backbone of therapy remains a purine nucleoside analog (PA), either in the form of cladribine or pentostatin which have traditionally been used as monotherapies. Addition of rituximab early in the induction treatment in combination with cladribine can deepen and prolong responses, as opposed to delayed rituximab administration or cladribine monotherapy, and is a safe first-line option. Because of the outstanding and prolonged responses, PA + rituximab should be considered

the standard of care in fit patients requiring first-line treatment for HCL.

Management of Relapsed HCL:- Therapy for relapsed/refractory disease is contingent on treatment previously received, response to prior therapy, and timing of recurrence. In patients with an initial response of 24 months or longer, re-treatment with a PA generally with rituximab is appropriate. PA + R was used by Chihara et al. in a subset of patients with HCL in first relapse, achieving a CR, 5-y FFS, and OS of 100% and uMRD in more than half of the relapsed cohort. In those patients with a response shorter than 24 months, an alternative therapy to the initial PA should be considered. Alternative therapies are BRAF/MEK Inhibitors, BTK inhibitor (BTKi) ibrutinib, Bendamustine and Anti-CD20 Monoclonal Antibodies and Bone Marrow Transplant, Cellular Therapy, and Emergent Therapies.

Hairy cell Leukemia

Nikita Oza, MD(Path), FIAC

Institution: Histopia Lab - A Culture of Excellence,
103-104 M.S.C Bank Employee Deepjyot Chs Ltd, Shimpoli Road,
Borivali (west), Mumbai-400092.

Introduction

- Hairy cell leukemia (HCL) is a rare, indolent lymphoproliferative neoplasm of mature B cells with a distinct clinical presentation that includes peripheral blood cytopenias, splenomegaly and a small number of circulating neoplastic cells with hair-like cytoplasmic projections
- Median age at diagnosis is approximately 55. Poor prognostic features, while somewhat variable in the literature, may include age, hemoglobin less than 10 g/dL, platelets less than 100, ANC less than 1000, the presence of lymphadenopathy, and massive splenomegaly.
- More common in whites and less in African, Asian and Arab populations
- Increased risk: farming and exposure to pesticides
- Smoking has been reported as a significant negative association and appears to be protective

Pathophysiology

- ***BRAF V600E mutation*** is the causal genetic event in the vast majority of HCL. Mutation constitutively activates BRAF by autophosphorylation of the protein and **downstream MEK-ERK signaling pathway**, leading to increased expression of genes involved in survival and proliferation and promoting leukemic transformation

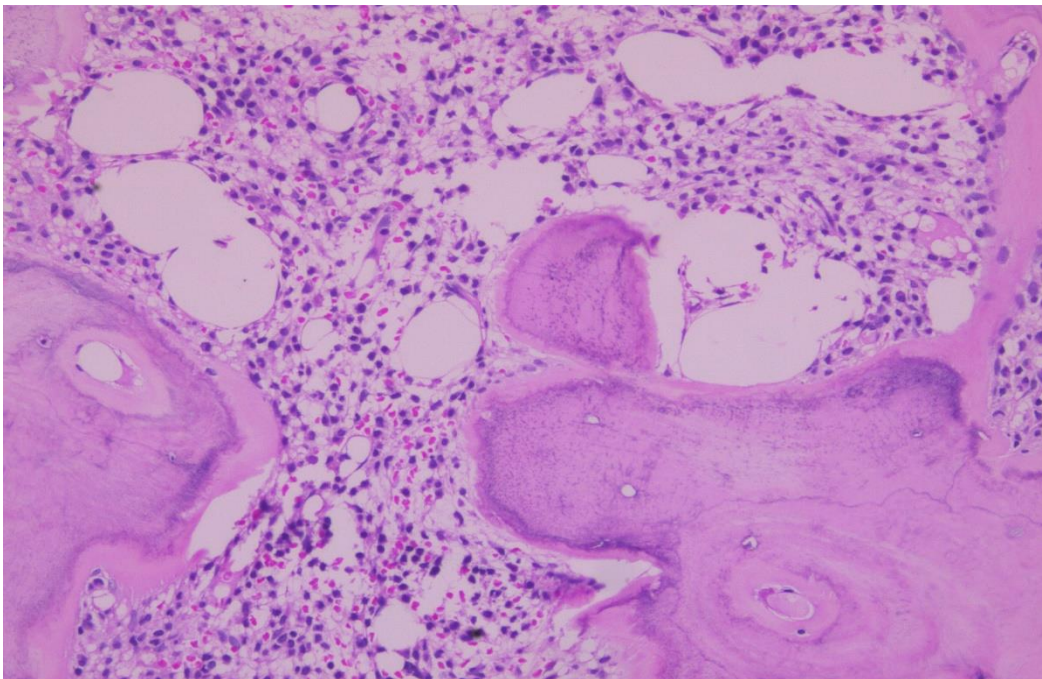
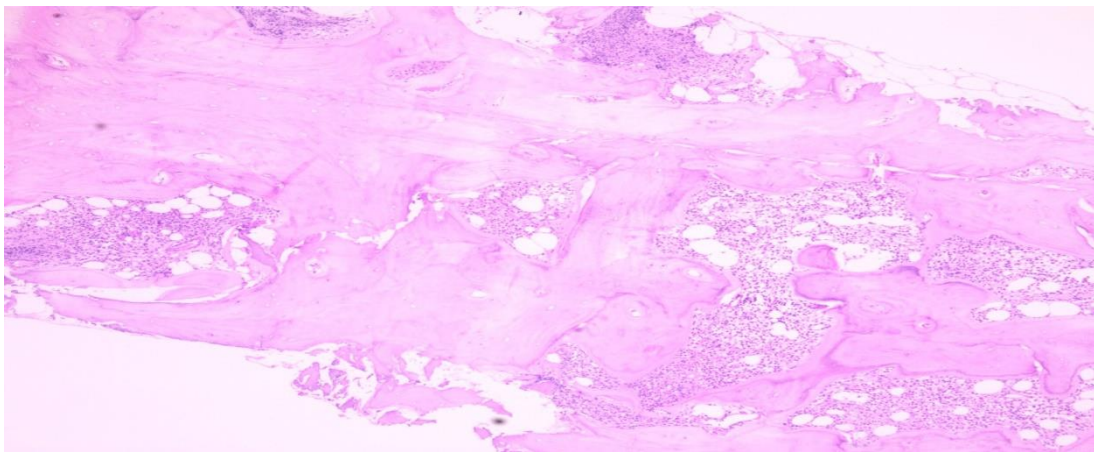
Prognostic factors

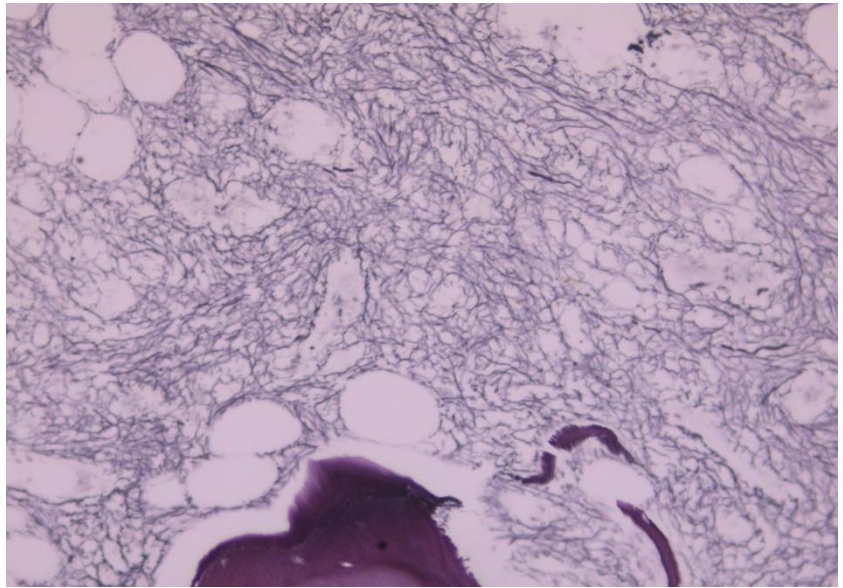
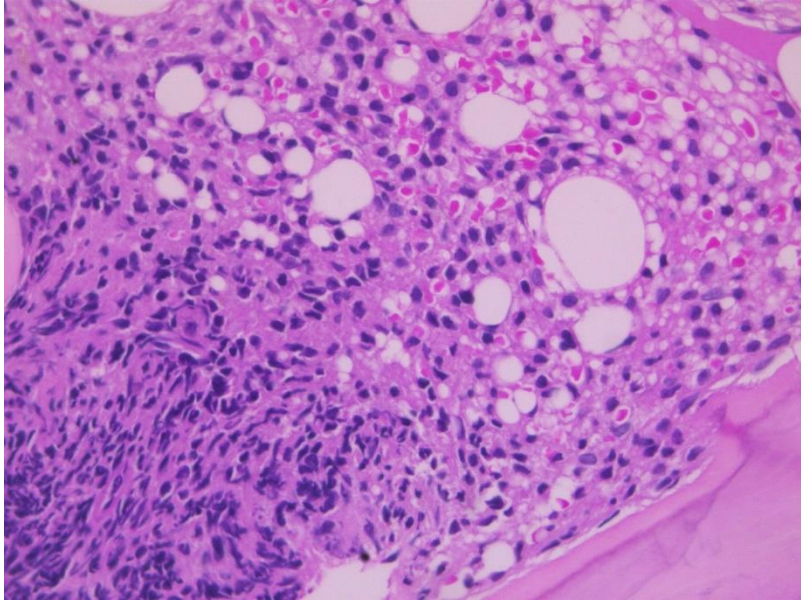
- Chronic, relatively indolent leukemia that predominantly responds well to current chemotherapy; 5 year event free survival rate after treatment is ~90%
- **Poor prognostic factors include:**
 - Massive splenomegaly, leukocytosis ($> 10 \times 10^9/L$), high number of neoplastic hairy cells in the blood ($> 5 \times 10^9/L$) and high beta2 macroglobulin
 - Unmutated *IGHV* status
 - *IGHV4-34* positive immunoglobulin variable heavy chain gene rearrangement
 - CD38 expression

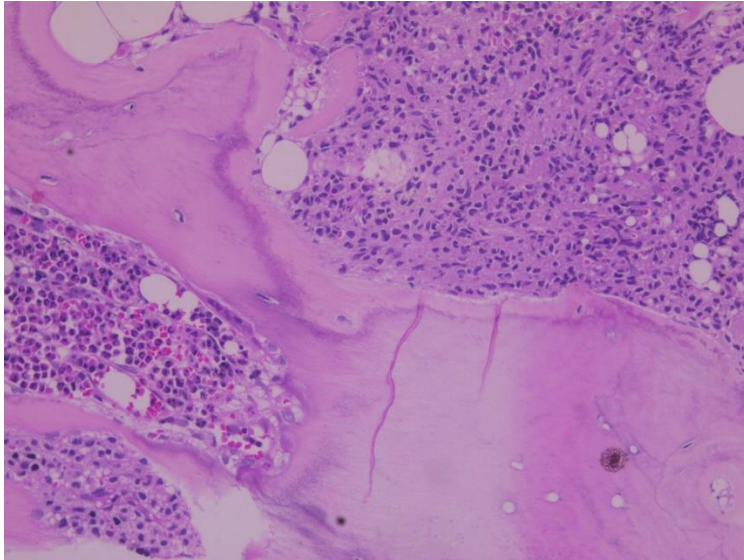
Clinical Details

- 68 year male presented with pancytopenia with abdominal discomfort
- **On examination:** Massive splenomegaly was noted with no significant lymphadenopathy
- Clinically suspicious for: Lymphoma ??
- Bone marrow biopsy was performed

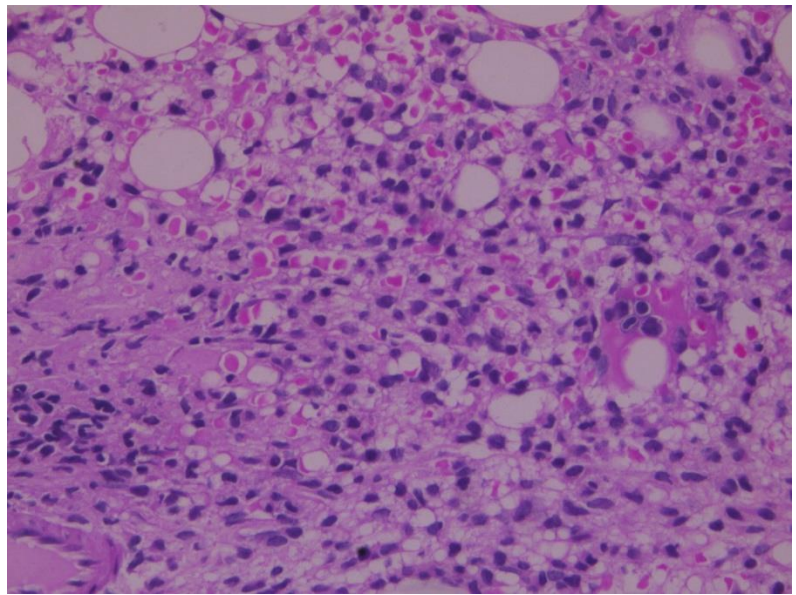
Gross: Two linear bone marrow biopsy received, largest measuring 0.8 cm in length. Specimen lightly decalcified and submitted entirely

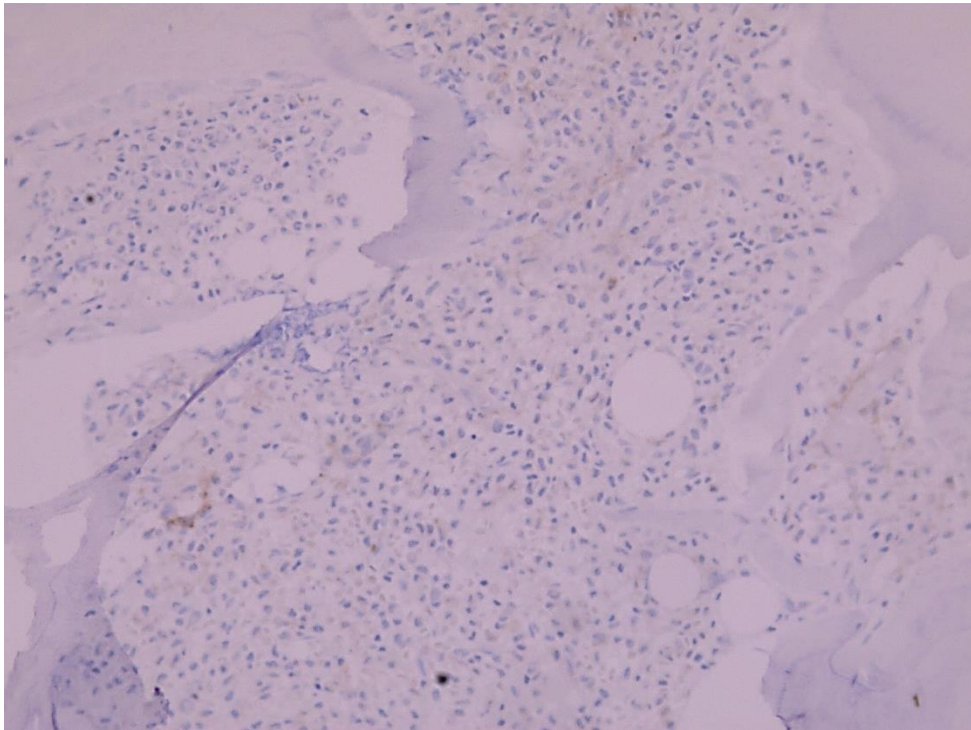
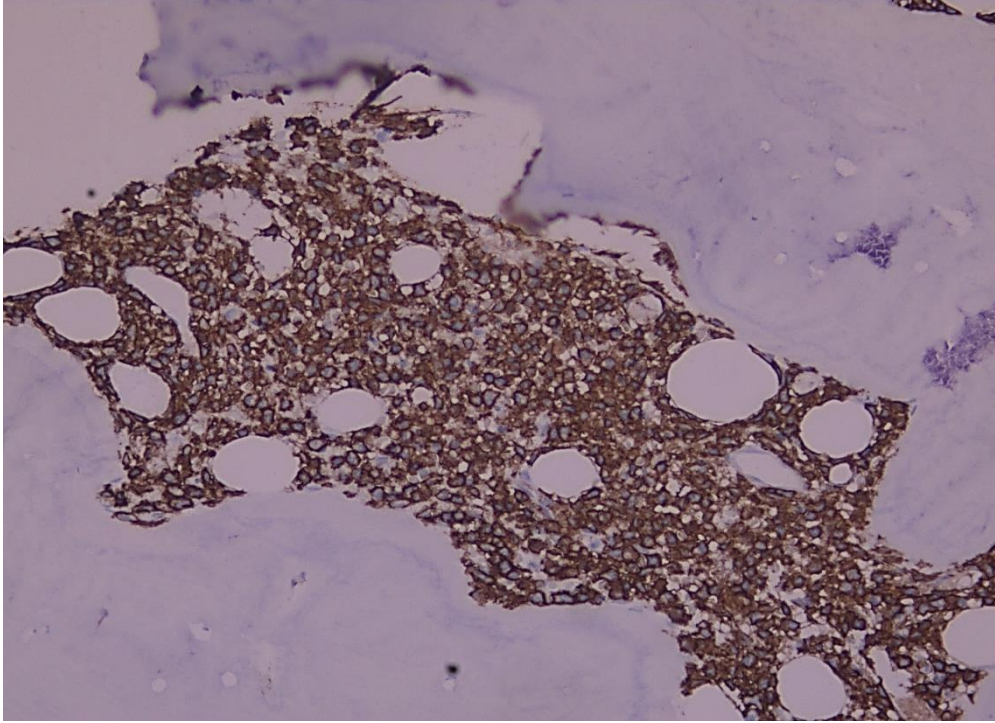




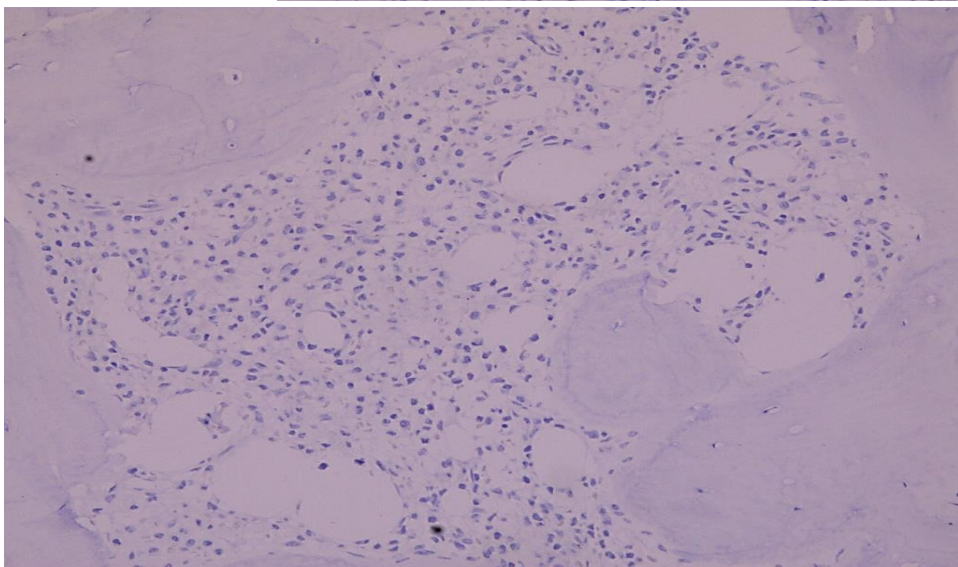
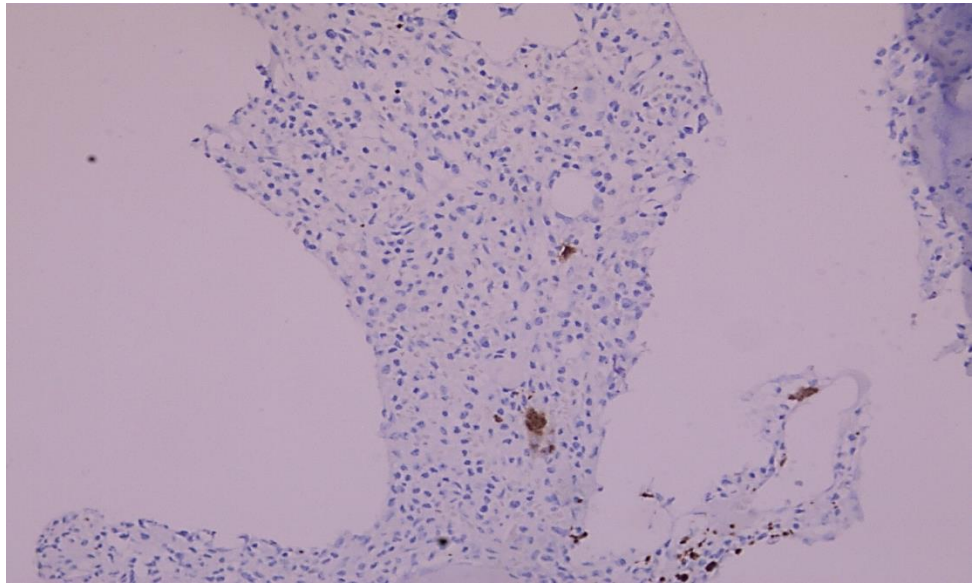
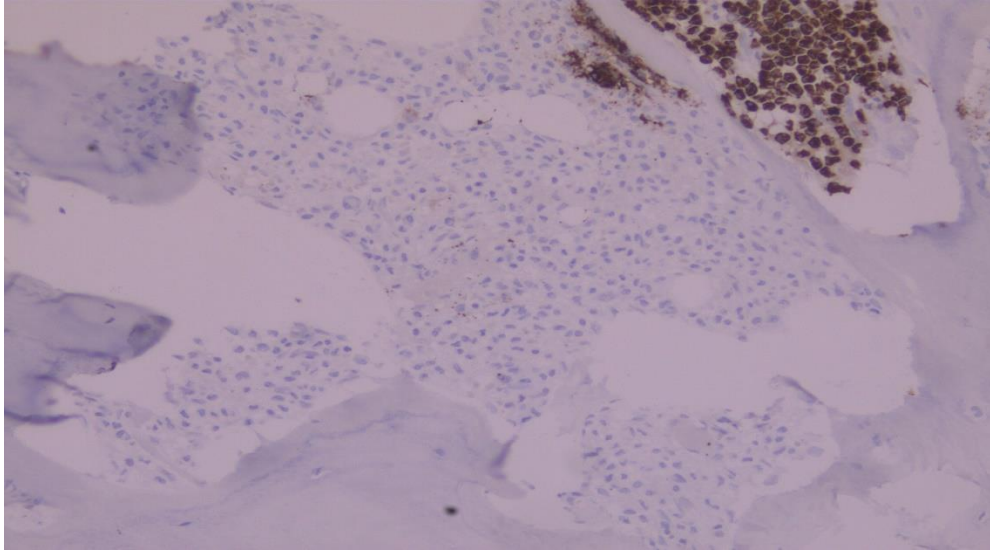


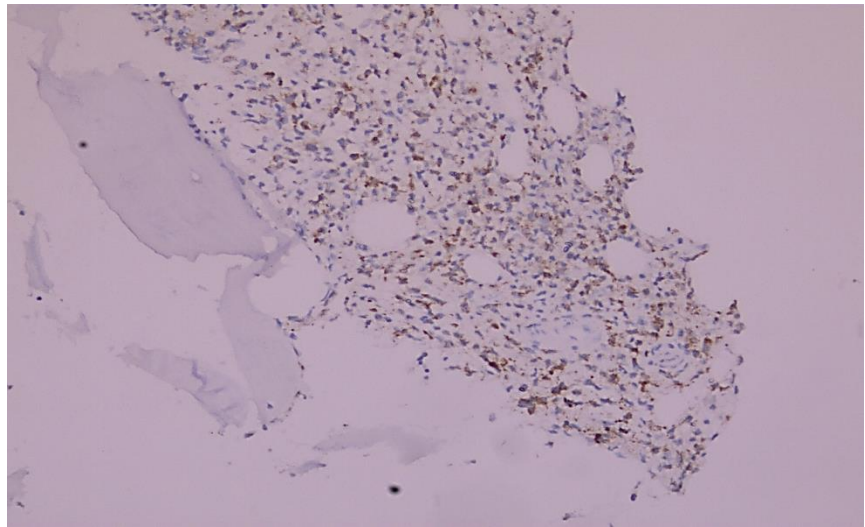
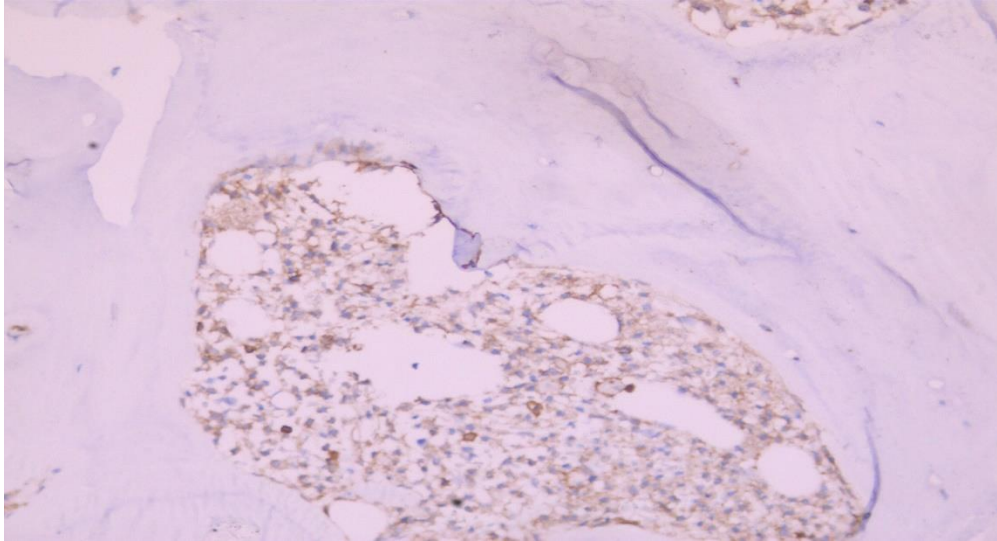
Interstitial and paratrabeular spaces showing small to intermediate size atypical lymphoid cell proliferation





Negative:
CD3, CD5, CD10, CD23, CD43, BCL6





Bone marrow biopsy: Marrow involved by low grade B cell lymphoma consistent with Hairy cell leukemia.

Comment: Correlation with flowcytometry immunophenotyping is advised.

Differential Diagnosis

- **HCL variant:** Typically has prominent nucleoli and less marrow infiltration. It is often associated with extreme leukocytosis, often without the neutropenia, monocytopenia, anemia, and thrombocytopenia seen in HCL.
- **Splenic diffuse red pulp small B cell lymphoma:** Typically does not express annexin A1, CD25, CD103, CD123, and CD11c.

- **Splenic marginal zone lymphoma:** Typically does not express CD103, CD11c, and CD25.
- **Other unclassifiable splenic lymphomas:**
 - **Mantle cell lymphoma:** Expresses CD5 and has strong expression of cyclin D1; it does not express CD25, CD103, or annexin A1. It also does not demonstrate hairy cytoplasm in lymphocytes.
 - **Chronic lymphocytic leukemia:** Expresses CD5 and lacks expression of CD103. It involves both red pulp and white pulp of the spleen while HCL predominantly involves red pulp.
 - **Prolymphocytic leukemia:** Marked the elevation of the white blood cell count, with the characteristic morphology of prolymphocytes and lack of hairy cytoplasmic projections.

Treatment

- Not curative; asymptomatic patients usually do not require treatment
- Standard therapy is purine analogues (i.e., cladribine, pentostatin), which are effective in the majority of HCL
- Late relapses are not uncommon; choices for relapsed and refractory HCL include moxetumomab (anti-CD22), pasudotox (anti-CD22), vemurafenib (BRAF inhibitor) and bendamustine plus rituximab
- Splenectomy as salvage therapy

Molecular Pathology

- *BRAFV600E* mutation is a hallmark for classical HCL; this mutation is not seen in HCL variant
- Rare cases that are *BRAFV600E* mutation negative will be positive for *IGHV4-34*
- Histone methyltransferase *KMT2C (MLL3)* and *CDKN1B* are commonly mutated genes in cHCL
- *BRD4*, *CEBPA*, *CREBBP*, *RUNX1*, *EP300* and *MED12*, Notch signaling (*NOTCH1* and *NOTCH2*) and DNA repair
- Deletions of chromosomes 7q and 13q and gains of chromosome 5

Conclusion

- Hairy cell leukemia is a relatively rare hematological malignancy and is best managed by an interprofessional team that includes an oncologist, hematologist, internist, and an infectious disease expert.
- There is no cure for hairy cell leukemia and without treatment life expectancy is about 4 years.
- Only symptomatic patients are treated with chemotherapy. Once treated, these patients need to be followed with regular monitoring of blood work
- High index of suspicion is essential for the diagnosis with judicious use of ancillary techniques

ORIGINAL ARTICLE: CLINICAL

Immunophenotyping of mature B-cell non Hodgkin lymphoma involving bone marrow and peripheral blood: critical analysis and insights gained at a tertiary care cancer hospital

SUMEET GUJRAL¹, SUNITA NARAYAN POLAMPALLI², Y. BADRINATH⁴,
ASHOK KUMAR⁴, SUBRAMANIAN P. G.⁴, REENA NAIR³, SUDEEP GUPTA³,
MANJU SENGAR³, & CHANDRALEKHA NAIR³

¹Department of Pathology, ²Department of Molecular Biology, ³Department of Medical Oncology, and ⁴Department of Hematopathology, Tata Memorial Hospital, Parel, Mumbai, India

(Received 28 January 2009; revised 21 April 2009; accepted 22 May 2009)

Abstract

We evaluated the diagnostic utility of flow cytometry immunophenotyping in bone marrow aspirates and peripheral blood, in the assessment of mature B-cell non-Hodgkin lymphoma (MBNHL). We analyzed 356 cases of MBNHL received for immunophenotyping over a 4 year period. All cases were reviewed, correlated with biopsy specimen (lymph node and splenectomy). Discrepant cases were re-evaluated. Common subtypes included chronic lymphocytic leukemia (CLL) (243 cases, 68.5%), follicular lymphoma (30 cases, 8.5%), mantle cell lymphoma (20 cases, 5.5%), splenic marginal zone lymphoma (18 cases, 5%), hairy cell leukemia (18 cases, 5%). CD5+/CD23+ had a high positive predictive value (PPV) for diagnosing CLL whereas CD5+/CD23- had a high negative predictive value (NPV) for diagnosing mantle-cell lymphoma (MCL). Limited panel of 9 antibodies mainly CD19, CD5, CD23, CD10, FMC7, kappa, lambda, CD3 and CD20 help diagnose more than 92% of cases of MBNHL. Minimal diagnostic panels become important in countries with limited resources.

Keywords: *Mature B cell non Hodgkin lymphoma, immunophenotyping, flow cytometry*

Introduction

The usefulness of flow cytometric immunophenotyping (FCIP) as an adjunct in the diagnosis and classification of mature B cell non-Hodgkin lymphoma (MBNHL) cannot be overemphasized. In rare circumstances, however, undue reliance on strict criteria may lead to a wrong diagnosis. Accurate interpretation of complex data not only is a daunting task for the cytometrists/pathologists not familiar with this art but also can be a challenge for the expert. The characteristic immunophenotypic characteristics of various lymphomas are well known; the diagnostic usefulness and limitations, however, have received little scrutiny [1,2]. Distinction between

MBNHL subtypes can be difficult due to overlap in cell morphology and immunologic features. Thus a variety of clinical, hematological, cytogenetic, and molecular features may be required to be evaluated in combination with morphology and immunophenotyping to accurately subtype MBNHL.

The purpose of this retrospective study was to illustrate the spectrum of subtypes and the immunophenotypic features of cases referred as MBNHL, based on World Health Organization (WHO) classification [3]. We also studied the positive predictive value (PPV), and negative predictive value (NPV) of antigenic combination of CD5/CD23 and other antibodies like FMC7 and CD79b, characteristic of each MBNHL subtype, and the significance of the

intensity of each antigen expression. We also report the incidence of usual and atypical immunophenotypes for each lymphoma group to emphasize the lack of complete faithfulness of any one immunophenotype for a particular lymphoma type.

Material and methods

We analyzed 410 consecutive samples (bone marrow (BM) and peripheral blood (PB)) received for FCIP in a 4 year period (between 2003 and 2007). Thirty out of these were follow-up cases and were excluded from the study. Out of the remaining 380 new cases, there were 356 cases of MBNHL, 12 cases of plasma cell disorders, three cases of Burkitt lymphoma, and nine cases of T-cell lymphoid neoplasm. Out of these consecutive 380 samples, 136 were BM aspirates and 244 were PB samples. Histological and immunohistochemical results of all tumors were reviewed, and final diagnosis was obtained from them.

Immunophenotype was determined on isolated EDTA collected PB and/or BM mononuclear cells by FCM with a panel of monoclonal antibodies (McAb) conjugated with Fluorescein iso-thiocyanate (FITC), Phycoerythrin (PE), and R-Phycoerythrin Cyanin 5 (R-PE CY.5) (Table I). Lyse and wash technique was performed to prepare the cells. Cells were incubated in dark for 30 min at room temperature and washed with phosphate buffered saline. Three color FCIP immunophenotyping was performed on FACS Calibur (Becton-Dickenson, San Jose, California) by collecting 10,000 ungated list mode events, selecting an appropriate gate on the combination of forward and side scatter, and analyzing cells with the most appropriate gate. Cell quest pro software was used. Tumor cells were stained with various combinations of fluorochrome. Appropriate isotypic controls were used.

Table I. Panel of monoclonal antibodies used with fluorochromes conjugates.

FITC	PE	R-PE.CY.5
Iso G1	Iso G1	Iso G1
CD5	CD23	CD38
CD22	CD19	CD3
FMC7	CD79b	CD10
Kappa	Lambda	CD20
IgM	IgD	SmIg
CD11c	CD103	CD25
CD56	CD138	CD38
CD56	CD2	CD16
CD4	CD3	CD8
TCRab	TCRgd	CD25

FITC, fluorescein iso-thiocyanate; PE, phycoerythrin; R-PE. CY.5, R-phycoerythrin cyanin 5.

Data analysis

An antigen was considered positive based on the antigenic intensity and the percentage positivity of the gated cells (> 20% of the gated cells). The antigenic intensity was graded on a four quadrant scatter plot. The fluorescence signals were recorded in logarithmic mode. Antigen expression was then classified as being negative (−), dimly positive (+), moderately positive (++), and strongly positive (+++) using arbitrary relative mean fluorescent intensity (MFI) values of 0 to 5, 5 to 10¹, 10¹ to 10² and more than 10², respectively on a log scale [4]. The positive and negative values (PPV and NPV) for CD5/CD23 antigenic combinations and for FMC7 and CD79b were calculated.

Results

There were 286 males and 70 females with M:F being 4:1. Age ranged from 9 to 80 years with median age of 57 years. Chronic lymphocytic leukemia (CLL) was the commonest subtype (68.5%) followed by follicular lymphoma (FL), mantle cell lymphoma (MCL), splenic marginal zone lymphoma (SMZL), hairy cell leukemia (HCL) (Refer Table II).

Cases were reviewed, correlated with BM, lymph node (LN) and splenic biopsies (wherever available) and the discrepant cases were re-evaluated. Lymph node biopsy was available in CLL (67 cases), FL (20 cases), MCL (seven cases), and diffuse large B-cell lymphoma (DLBCL) (four cases). Splenectomy specimen was available in SMZL (four cases) and HCL (one case). Table III shows the number of cases where the diagnosis was revised after re-evaluation.

Table II. Incidence of MBNHL.

B-CLPD (n = 356)	No. of cases	(%)
CLL	243	68.5
CLL/PLL	5	1.5
FL	30	8.5
MCL	20	5.5
SMZL	18	5
HCL	18	5
LPL/WM	2	0.5
DLBCL	5	1.5
B NHL unclassified	15	4

CLL, chronic lymphocytic leukemia; CLL/PLL, prolymphocytic leukemia; FL, follicular lymphoma; MCL, mantle cell lymphoma; SMZL, splenic marginal zone lymphoma; HCL, hairy cell leukemia; DLBCL, diffuse large B-cell lymphoma; MBNHL, mature B-cell non Hodgkin lymphoma; B-CLPD, B cell chronic lympho-proliferative disorder; LPL/WM, lymphoplasmacytic lymphoma/Waldenstrom's macroglobulinemia; B NHL unclassified, B cell non Hodgkin Lymphoma, unclassified; LN, lymph node; BM, bone marrow; SLL, small lymphocytic lymphoma.

Consensus diagnosis was based on combining aspirate and tissue morphology, FCIP and immunohistochemistry studies. Discordance between FCIP and tissue biopsy was seen in 27 cases (10.4%). Discordance was commonly observed in SMZL (28%), MCL (25%), and CLL (5%). HCL, CLL-prolymphocytic leukemia (CLL/PLL) and DLBCL did not show any discrepancy.

Expression patterns of CD5, CD23, FMC7 and CD79b were studied in relation to various subtypes of MBNHL (Refer Table IV). Cases were broadly grouped into four categories based on the combination of antigenic expression of CD5 and CD23. PPV

and NPV of these antigenic expression patterns were then calculated.

Expression pattern of CD5/CD23 in mature B-cell non Hodgkin lymphoma

CD5+/CD23+. CD5+/CD23+ antigenic expression pattern is usually seen in CLL and CLL/PLL [1,2]. This pattern was seen in 85% of CLL and 80% of CLL/PLL with a high PPV of 98%. Other cases showing such included FL (one case), SMZL (one case) and B NHL unclassifiable (two cases). Diagnosis of FL and SMZL were confirmed based on LN and splenic

Table III. Correlation between FCIP, LN, and BM biopsy.

Final diagnosis after evaluation (n = 356)	Original diagnosis retained	Revised diagnosis after evaluation	Original diagnosis in which diagnosis was revised	Discordance rate
CLL (n = 243)	232	11	MCL (5 cases), B NHL (5 cases), CLL/PLL (1 case)	5%
FL (n = 30)	27	3	SMZL (1 case), B NHL (2 cases)	10%
MCL (n = 20)	15	5	B NHL (4 cases), CLL (1 case)	25%
SMZL (n = 18)	13	5	B NHL (5 cases)	28%
HCL (n = 18)	18	0	–	–
B NHL (n = 15)	12	3	SMZL (2 cases), Inconclusive (1 case)	20%
CLL/PLL (n = 5)	5	0	–	–
DLBCL (n = 5)	5	0	–	–
LPL/WM (n = 2)	2	0	–	–

FCIP, flow cytometric immunophenotyping; CLL, chronic lymphocytic leukemia; CLL/PLL, prolymphocytic leukemia; FL, follicular lymphoma; MCL, mantle cell lymphoma; SMZL, splenic marginal zone lymphoma; HCL, hairy cell leukemia; DLBCL, diffuse large B-cell lymphoma.

Table IV. Expression pattern of CD5/CD23 and FMC7/CD79b in various MBNHL.

Immunophenotype	SLL/CLL N = 243	CLL/PLL N = 5	MCL N = 20	FL N = 30	SMZL N = 18	HCL N = 18	DLBCL N = 5	LPL/WM N = 2	B-NHL N = 15
CD5+/CD23+	208/85%	4/80%	0	1/3.5%	1/5.5%	0	0	0	2/13.5%
FMC7-/CD79b-	142 (32)/57%	1/20%	0	0	0	0	0	0	0
FMC7-CD79b+	47 (15)/19%	1/20%	0	0	0	0	0	0	0
FMC7+/CD79b-	14 (3)/6%	1 (1)/20%	0	0	1 (1)/5.5%	0	0	0	0
FMC7+/CD79b+	5 (3)/2%	1 (1)/20%	0	1(1)/3.5%	0	0	0	0	2/13.5%
CD5+/CD23-	11/5%	0	19/95%	2/7%	1/5.5%	7/38.5%	1/20%	0	3/21%
FMC7-/CD79b-	5 (3)/2%	0	2 (2)/10%	0	0	2/11%	0	0	1/7%
FMC7-/CD79b+	6 (4)/3%	0	7 (3)/35%	0	0	1/5.5%	0	0	1/7%
FMC7+/CD79b-	0	0	4 (1)/20%	0	1 (1)/5.5%	0	0	0	1/7%
FMC7+/CD79b+	0	0	6/30%	2 (2)/7%	0	4/22%	1(1)/20%	0	0
CD5-/CD23+	22/9.5%	1/20%	0	12/39%	5/27.5%	1/5.5%	1/20%	0	4/24.5%
FMC7-/CD79b-	17 (4)/7%	0	0	0	0	0	0	0	1 (1)/7%
FMC7-/CD79b+	3 (2)/1.5%	1 (1)/20%	0	1/3.5%	0	0	0	0	0
FMC7+/CD79b+	1(1)/ 0.5%	0	0	0	2 (1)/11%	0	0	0	0
FMC7+/CD79b+	1 (1)/ 0.5%	0	0	11(5)/35.5%	3 (1)/16.5%	1/5.5%	1(1)/20%	0	3/17.5%
CD5-/CD23-	2/0.5%	0	1/5%	15/50.5%	11/61.5%	10/56%	3/60%	0	6/41%
FMC7-/CD79b-	0	0	0	2 (2)/7%	0	1/5.5%	0	0	1/7%
FMC7-/CD79b+	1 (1)/0.25%	0	1 (1)/5%	3(3)/10%	3 (2)/16.5%	1/5.5%	0	1	0
FMC7+/CD79b-	0	0	0	2 (2)/7%	1 (1)/5.5%	4/22.5%	1/20%	0	1/7%
FMC7+/CD79b+	1(1)/0.25%	0	0	8 (3)/26.5%	7 (2)/.5%	4/22.5%	2/40%	1	4/27%

Figures in brackets indicate number of cases where diagnosis was confirmed on tissue biopsy. MBNHL, mature B-cell non Hodgkin lymphoma; CLL, chronic lymphocytic leukemia; CLL/PLL, prolymphocytic leukemia; FL, follicular lymphoma; MCL, mantle cell lymphoma; SMZL, splenic marginal zone lymphoma; HCL, hairy cell leukemia; DLBCL, diffuse large B-cell lymphoma; LPL/WM, lymphoplasmacytic lymphoma/Waldenstrom's macroglobulinemia.

biopsy respectively. Remaining two cases were labeled as B NHL unclassifiable [5]. NPV for CD5+/CD23+ was 73% in CLL and CLL/PLL.

CD5+/CD23-. CD5+/CD23- antigenic expression pattern suggestive of MCL [1,2], was expressed in 19/20 cases (95%) of MCL, with a high NPV of 99%. One case was labeled as MCL based on a LN biopsy. Six cases of MCL also underwent LN biopsy. It had a low PPV of 46% for MCL, as this pattern was also seen in other B MBNHL like CLL (11 cases, 5%), FL (two cases, 7%), SMZL (one case, 5.5%), HCL (seven cases, 38.5%), DLBCL (one case, 20%) and B NHL unclassifiable (three cases, 21%). The diagnosis of all these cases were confirmed based on LN biopsy (for CLL, FL, DLBCL), and splenectomy specimen (for SMZL), and expression of other antigens like CD25, CD103, CD11c in HCL. Three cases were labeled as B NHL unclassifiable. Four cases of CLL did not have LN biopsy for confirmation, and were diagnosed based on BM morphology, clinical features and rest of the immunoprofile including negative expression of FMC7 (Table IV).

CD5-/CD23+. CD5-/CD23+ phenotype is usually seen in FL, DLBCL, and SMZL [1,2]. This phenotype had a low PPV of 47% but a good NPV of 80%, for diagnosis of FL, DLBCL, and SMZL. This phenotype was expressed in other subtypes as well (9.5% of CLL, 20% of CLL/PLL, 5.5% of HCL and 24.5% of B NHL unclassifiable). Eight out of 22 CLL cases had a LN diagnosis for confirmation, whereas rest 14 cases were diagnosed based on rest of the immunoprofile and FMC7 negativity [5] (Table IV), BM morphology, and clinical features.

CD5-/CD23-. This phenotype is usually seen in FL, DLBCL, SMZL, and HCL [1,2]. It had a good PPV and NPV (93% and 86%, respectively), to detect these cases except in two cases of CLL and one case of MCL which were confirmed on a LN biopsy evaluation. There were six cases with this phenotype, which could not be classified and were labeled as B NHL unclassifiable.

Expression pattern of FMC7/CD79b

FMC7 is usually absent in CLL, while CD79b is negative or dimly expressed [2]. FMC7 and CD79b were expressed in 10% and 29% of CLL cases. Out of the 208 cases of CLL which were CD5+/CD23+, FMC7 was expressed in 19 cases (8%) only, while CD79b was expressed in 52 cases (21%). FMC7 was expressed in three out of 35 cases (8.5%), CD79b in 12 out of 35 cases (34%) of atypical CLL (CD5 negative CLL). There was again a significant

difference between the OR for the expression of FMC7 and CD79b in atypical CLL. The PPV and NPV for FMC7 in diagnosis of CLL had been 80%. The PPV and NPV for CD79b was 80% and 50%, respectively.

Intensity of each antigenic expression in different MBNHL subtypes was analyzed (Table V). CD19 had a predominantly strong expression in HCL (89%) and SMZL (67%), moderate to strong expression in CLL and MCL and moderate expression in FL (80%). CD5 had a predominantly moderate expression in CLL (69%) and MCL (85%), moderate to strong expression in FL (10%) and SMZL (12%). CD23 had strong expression in 82% of CLL, while it was absent in all cases of MCL and HCL (except one case). CD23 was also expressed in FL (43%) and SMZL (33%) and a few cases even showed moderate to strong expression. The expression of CD20 was strong in HCL (88%), SMZL (72%) and FL (67%) while it showed a moderate expression in CLL (63%) and MCL (85%). CD22 had a moderate expression in SMZL (83%), moderate to strong expression in MCL (67%), and weak to moderate expression in CLL (49%) and FL (52%). There was no statistical difference between the antigenic intensities of CD20 and CD22 to differentiate CLL from non CLL cases. Also neither CD20 nor CD22 helped to differentiate between CD5+/CD23- CLL from MCL (Table VI). CD79b showed a weak to moderate expression in CLL (26%). It had a moderate to strong expression in FL, MCL and MZL. FMC7 was absent in 90% of CLL cases, and in rest 10% of cases, it showed a heterogeneous expression. It was also absent in 47% of MCL cases, while in rest of the cases, it showed a moderate to strong expression. These were confirmed on LN biopsy as cyclin D1 positive MCL. The expression of FMC7 in FL, SMZL and HCL was predominantly moderate. The expression of SmIg was moderate to strong in all the cases. However, the strong intensity of SmIg in MCL helped to differentiate MCL from CD23 negative CLL. SmIg had a strong expression in 60% cases of MCL as against 14.5% in CD23 negative CLL. This difference was significant (OR for MCL=4, OR for CLL=0.2, $P < 0.05$, Table VI). IgM showed a moderate to strong expression in all the CLPD cases but was commonly expressed in SMZL, MCL, and FL. CD38 showed a heterogeneous expression pattern in CLL (44%) and FL (54%), while it was uncommon in HCL and SMZL. It showed a moderate expression pattern in MCL. CD10 showed moderate to strong expression in 93% of FL cases. CD11c had predominantly strong expression in 67% of HCL cases and rest of the cases showing moderate expression. CD25 was

Table V. Intensity of antigenic expression in MBNHL.

	CLL			MCL			FL			SMZL			HCL		
	-	+	+++	-	+	+++	-	+	+++	-	+	+++	-	+	+++
CD 19	-	102, 42%	141, 58%	-	9, 45%	11, 55%	-	24, 80%	6, 20%	-	6, 33%	12, 67%	-	2, 11%	16, 89%
CD 5	24, 10%	168, 69%	41, 17%	1, 5%	17, 85%	1, 5%	27, 90%	2, 7.5%	1, 2.5%	16, 88%	1, 6%	1, 6%	11, 61%	7, 30%	-
CD 23	13, 5%	30, 12%	198, 82%	20, 100%	-	-	17, 57%	7, 23%	6, 20%	12, 67%	3, 6.5%	3, 6.5%	17, 94%	-	1, 6%
CD 20	19, 8%	148, 63%	61, 26%	1, 5%	17, 85%	1, 5%	2, 6%	8, 27%	20, 67%	1, 5%	1, 5%	13, 72%	1, 6%	1, 6%	14, 88%
CD 22	120, 50% (1)	84, 34.5% (4)	1, 0.5%	5, 28% (3)	1, 5%	5, 28%	13, 48%	3, 11%	11, 41%	1, 6%	15, 83%	2, 11%	5, 33%	4, 27%	6, 40%
CD 79B	177, 73%	45, 19%	3, 1%	5, 28%	-	11, 61%	4, 14%	-	13, 46%	11, 40%	1, 5%	10, 56%	7, 48%	6, 40%	1, 6%
FMC7	207, 90%	18, 8%	3, 1.5%	8, 47%	-	5, 29%	4, 24%	1, 3.5%	19, 68%	1, 3.5%	1, 5.5%	13, 72%	5, 34%	9, 60%	1, 6%
Smlg	36, 18%	116, 57%	27, 13%	2, 12%	1, 6%	4, 24%	9, 58%	-	7, 30%	17, 70%	-	5, 33%	1, 9%	4, 33%	7, 58%
CD38	76, 66%	8, 7%	6, 5%	4, 40%	-	6, 60%	5, 46%	2, 18%	2, 18%	8, 80%	1, 10%	7, 88%	1, 12%	-	-
IgM	101, 52%	66, 34%	17, 9%	2, 14%	-	7, 50%	5, 36%	5, 21%	6, 25%	13, 54%	2, 12.5%	6, 37.5%	5, 42%	1, 8%	1, 8%
CD10	240, 99.5%	-	1, 0.5%	19, 100%	-	-	2, 7%	-	22, 73%	6, 20%	-	12, 67%	16, 100%	-	-
CD11c	1, 25%	3, 75%	-	2, 67%	-	1, 33%	1, 100%	-	-	3, 50%	-	-	6, 33%	-	6, 33%
CD25	4, 100%	-	-	2, 100%	-	-	1, 100%	-	-	6, 100%	-	-	3, 17%	8, 44%	1, 6%
CD103	4, 100%	-	-	2, 100%	-	-	1, 100%	-	-	6, 100%	-	-	3, 16%	10, 56%	5, 28%
Kappa	108, 72%	4, 2%	34, 23%	9, 48%	-	5, 26%	5, 26%	12, 41%	3, 11%	14, 48%	5, 28%	10, 59%	4, 24%	3, 17%	
lambda	139, 57%	2, 1%	48, 20%	10, 52%	-	3, 16%	6, 32%	17, 61%	-	11, 39%	13, 72%	7, 41%	-	3, 18%	

MBNHL, mature B-cell non Hodgkin lymphoma; CLL, chronic lymphocytic leukemia; FL, follicular lymphoma; MCL, mantle cell lymphoma; SMZL, splenic marginal zone lymphoma; HCL, hairy cell leukemia.

-, no expression; +, weak expression; ++, moderate expression; ++++, strong expression.

Table VI. Intensity of antigenic expression in classical CLL (CD5+/CD23+), atypical CLL (CD5+/CD23-), and MCL (CD5+/CD23-).

	Classical CLL CD5+/CD23+ (n = 208)			Atypical CLL CD5+/CD23- (n = 11)			MCL CD5+/CD23- (n = 19)				
	-	+	+++	-	+	+++	-	+	+++		
CD19	Nil	Nil	83, 40%	Nil	Nil	5, 45%	6, 55%	Nil	Nil	8, 42%	11, 58%
CD5	Nil	9, 4%	160, 77%	Nil	1, 9%	8, 73%	2, 18%	Nil	Nil	17, 90%	1, 5%
CD23	Nil	2, 1%	22, 11%	11, 100%	Nil	Nil	Nil	19, 100%	Nil	Nil	Nil
CD20	19, 9%	7, 2%	124, 61%	Nil	Nil	7, 70%	3, 30%	1, 5%	1, 5%	16, 85%	1, 5%
CD22	99, 48%	34, 17%	73, 35%	Nil	1, 9%	8, 73%	Nil	7, 41%	1, 6%	6, 35%	3, 18%
CD79B	154, 74%	16, 8%	36, 17%	1, 1%	5, 45%	Nil	1, 10%	5, 29.5%	Nil	10, 59%	2, 11.5%
FMC7	186, 90%	1, 0.5%	16, 8%	2, 1.5%	11, 100%	Nil	Nil	10, 53%	Nil	5, 26%	4, 21%
Smlg	30, 17.5%	21, 12%	96, 56%	24, 14.5%	Nil	9, 82%	2, 18%	2, 13%	1, 7%	3, 20%	9, 60%

CLL, chronic lymphocytic leukemia; MCL, mantle cell lymphoma.

absent in 33% of HCL cases, while in rest it had weak to moderate expression. CD103 showed weak to strong expression in all cases of HCL.

Discussion

Current knowledge of MBNHL immunophenotyping is primarily based on studies of individual disease entities [6]. The findings of these studies have often been extrapolated with the inference that the described immunophenotypes are diagnostic of the corresponding disease entity. For instance, CD5 and CD23 co-expression by a MBNHL is often considered diagnostic of CLL/SLL, and the absence of CD23 in a CD5+ MBNHL is suggestive of MCL, confirmed with cyclin D1 immunohistochemistry or karyotyping t(11;14) [7]. Likewise, CD10 positivity is considered to favor strongly a diagnosis of FL; CD25, dual CD11c/CD22, and CD103 have all been touted as being 'diagnostic' markers of HCL [8,9]. These assumptions have become widely accepted, and yet the reliability of FCIP in accurately predicting MBNHL diagnoses in subsequently obtained tissue biopsy specimens has not been systematically examined. We retrospectively reviewed MBNHL cases (BM and PB) and the corresponding diagnostic tissue biopsy specimens. Goal was to determine the ability of FCIP to predict MBNHL classification and thereby to formulate a diagnostic algorithm for MBNHL sub classification on the basis of FCIP. The cases were broadly grouped into four categories based on the combination of antigenic expression of CD5 and CD23. The PPV and NPV of different patterns of CD5/CD23 combination, and of FMC7 (and CD79b) were calculated. By using this algorithm we could subtype 92% of our cases (mainly CLL, FL, MCL and SMZL). HCL is suspected on clinical findings and morphology and the immunophenotypic panel is accordingly planned. Most other cases also had a classical morphology on a Giemsa stain PB or BM aspirate like small cleaved cells of follicular and MCLs and soccer ball like chromatin of round cells of CLL.

These leukemia cases were referred to our laboratory for diagnosis and further sub-typing. We do not perform FCIP on staging marrows, where a morphological evaluation is followed by IHC (if necessary). Though the frequency of BM involvement in staging marrows for lymphoma has been reported quite variably in the literature [10], no data exist in the literature recommending use of FCIP to detect lymphoma involvement in staging BM specimens. Incidence of BM involvement in staging marrows in case of peripheral lymphomas at our center is 31% in B-cell lymphoma and 30% in T-cell lymphomas (unpublished data). However cases presenting as

leukemia are predominantly of B cell phenotype, where MBNHL constituted 98% while T-cell NHL were only 2% of all the mature lymphoid neoplasm. Discordance between diagnosis by FCM and tissue biopsy was seen in 27 cases (10.4%). It was seen that SMZL had the highest discordance rate (28%), followed by MCL (25%). High discordance rate in SMZL could be attributed to unavailability of any definitive diagnostic criteria which remains a diagnosis of exclusion. Cyclin D1 works well on the biopsy sections but has limitations on the FCIP [6]. Rate of immunophenotypic discrepancies of antigen expression in NHL involving different anatomic sites simultaneously has been studied insufficiently. Discordance rates have been reported to vary from 10 to 22% [11,12].

Chronic lymphocytic leukemia

It was the commonest subtype in our study (68.5%). Matutes *et al.* have proposed a scoring system based on the expression and staining intensity of various markers (CD5, CD22, CD23, FMC7, and SmIg) and reported that the absence of expression of FMC7 is one of the most reliable markers, that differentiates CLL from other B-cell neoplasms [5,13]. We used this scoring system to distinguish CLL from other MBNHL cases.

CD5 positive CLL: CD5+/CD23+ phenotype which is pathognomonic of CLL, was seen in 208 cases (85%) and had PPV of 98%. PPV and NPV for CD5/CD23 for diagnosis of MBNHL have not been extensively studied. Kaleem *et al.* have shown that the phenotype of CD5+/CD23+ for diagnosis of SLL/CLL was highly specific and had a high PPV (93%) and NPV (99%), but was observed in only 90% of the cases [14]. NPV for this phenotype to diagnose CLL was only 73%, as rest 15% of CLL cases showed other expression patterns of CD5/CD23 i.e. 5% showed CD5+/CD23- phenotype, 9.5% showed CD5-/CD23+ phenotype and rest 0.5% showed CD5-/CD23- phenotype. All these cases were labeled as atypical CLL. In the study conducted by Kaleem *et al.*, 10% of CLL cases showed other CD5/CD23 phenotypes, out of which 7% showed CD5+/CD23- pattern [14]. Frequency of CD23 negativity in CLL is very low and support the hypothesis that most cases reported as CLL with CD23 negativity were actually leukemic phase of NHL [15], commonly MCL [16,17]. In some patients, it may be difficult to distinguish between CLL and MCL on FCM and these cases might need a LN biopsy for confirmation. When we analyzed the expression of SmIg, CD20, CD22, FMC7 and CD79b to find out which of these markers help to differentiate CD23 negative CLL from MCL, it was

observed that strong expression of SmIg in MCL helped to differentiate MCL from CD23 negative CLL. SmIg had a strong expression in MCL (60%) as against 14.5% in CD23 negative CLL. This difference was significant (OR for MCL=4, OR for CLL=0.2, $P < 0.05$, Table VI). Though absence of FMC7 favored a diagnosis of CLL in all 11 cases (100%) with CD5+/CD23- phenotype, it however did not help to differentiate from MCL, because 10/19 cases (53%) of MCL showed absence of FMC7. These cases were differentiated from each other because of different antigenic intensity levels of SmIg. Matutes *et al.* have also reported that high-intensity SmIg expression, and a high percentage of FMC7+ cells, with the CD19+/CD5+ and CD23- phenotype is most consistent with MCL [5]. Although few of the studies have shown that CD22 and CD20 expression help to differentiate CLL from MCL or other non CLL cases, with both, CD22 and CD20 showing dim expression in CLL and bright expression in non CLL cases [4,16–20], our study did not show such discrimination. Expression of CD22 and CD20 was moderate in CLL as well as in non CLL cases (Table V), a finding supported by Monaghan *et al.* [21] and Delgado *et al.*, [22] who have shown that CD20 is of little diagnostic value in differentiating CLL from other MBNHL. Also the expression CD79b was of little diagnostic value in discriminating CLL from non CLL cases, since CD79b was expressed in 21% of CLL cases with low NPV of 50%. However on the other hand, FMC7 was expressed in only 10% of CLL, in comparison to 15% as reported elsewhere [22] with a good PPV and NPV of 80% respectively. Thus FMC7 can be used as a useful marker to differentiate CLL from non CLL cases in combination with analysis of intensity of SmIg and the continued use of these two antibodies has been recommended [4,21,22].

CD5 negative CLL: Several recent studies have identified a subset of 'CD5- negative CLLs' which reportedly constitute from 0 to 36% of CLL [23–31]. In our study CD5 negative CLL constituted 10% (24 cases) of all CLL cases, out of which 9.5% had CD5-/CD23+ phenotype and 0.5% had CD5-/CD23- phenotype. Twenty one out of 24 cases had absence of FMC7 and moderate SmIg expression and therefore were labeled as such based on CLL scoring system [5]. Rest of the three cases where FMC7 was positive, and were labeled as CLL after LN biopsy correlation. But these cases also showed moderate expression of SmIg as against strong expression which was seen in non CLL cases. Sheikh *et al.*, [32] have shown that these cases may represent somewhat unusual MBNHL, with morphologic features and immunophenotypic profile not readily

classifiable, but which are certainly atypical for classic CLL. Some of these features are reminiscent of those seen in SMZL.

Mantle cell lymphoma

MCL constituted 5.5% of all MBNHL. CD5+/CD23- antigenic expression pattern which is classical of MCL [33], was expressed in 19/20 cases (95%) of MCL, with a high NPV of 99%. Absence of this pattern ruled out the diagnosis of MCL except for one case. The neoplastic cells in an individual case of MCL are most often monotonous and small with irregular nuclear contours [33,34]. Immunophenotypically, the neoplastic cells have a CD5+ monoclonal B-cell phenotype, do not express CD23, may rarely express CD10, and have moderately intense surface immunoglobulin expression [4,35,36]. But this expression pattern had a low PPV of 46% for MCL, as this pattern was also seen in other MBNHL. One case of MCL diagnosed on LN biopsy revealed CD5 negativity (FITC labeled) on FCIP. Unusual cases of bcl-1+ and CD5- MCL have been reported in literature, which pose a practical challenge for correct diagnosis and management [37–39].

Follicular lymphoma

FL constituted 8.5% of all MBNHL. FL usually has CD5-/CD23-/CD10+ or CD5-/CD23+/CD10+ phenotype [40]. In our study, 50.5% (15 cases) showed CD5-/CD23-/CD10+ phenotype and 39% (12 cases) showed CD5-/CD23+/CD10+ phenotype. CD5-/CD23-/CD10+ had a good PPV and NPV (93% and 86%, respectively). However, CD5-/CD23+/CD10+ had a low PPV of 43%. Another study has revealed that 30% of FL express CD23 with CD10, and another 5% express only CD23 [14]. Despite the fact that a substantial proportion of FLs may express CD23, several authoritative sources do not indicate CD23 expression as a variable feature of FL [40]. There were three cases of FL that were CD5 positive (confirmed on biopsy), out of which one case was CD23 positive and the rest two were CD23 negative. The co-expression of CD5 and CD10 is highly unusual because CD5 is expressed by a subpopulation of prefollicular mantle zone cells that lose CD5 as they differentiate into follicular cells and acquire CD10 [20]. Rarely CD5 has been expressed in conjunction with CD10 in cases with well-documented diagnoses of FL [41–45]. There were two cases of FL which were CD10 negative (7%). CD10 is a marker for germinal center (GC) B cells, and its expression suggests that GC B cells are a normal counterpart of

FL [46]. However, some reports, described the existence of CD10 negative FL, especially in high-grade (grade 3) FL [47–50].

Splenic marginal zone lymphoma

SMZL constituted 5.5% of MBNHL cases. Eleven out of 18 cases (61.5%) showed the CD5–/CD23– phenotype, while five cases (27.5) showed CD5–/CD23+ phenotype. PPV and NPV for CD5–/CD23– phenotype to detect SMZL was 93% and 86%, respectively, however the PPV for CD5–/CD23+ was low (43%). There was one case each of SMZL which showed CD5+/CD23+ and CD5+/CD23– phenotype respectively. Diagnosis of SMZL by FCIP is usually by exclusion. Positivity for CD5 in SMZL has been reported in few cases [51,52].

Hairy cell leukemia

HCL also constituted 5.5% of MBNHL cases. CD25 was expressed in only two thirds of cases, consistent with previously reported figures (66–75%) [53,54], whereas CD11c and CD103 were more consistent marker, found in all of our 18 cases (Table VII). Ten out of 18 cases (56%) showed the typical CD5–/CD23– phenotype, seven cases (38.5%) showed CD5+/CD23– phenotype and one case showed CD5–/CD23+ phenotype. PPV and NPV for CD5–/CD23– phenotype to detect HCL were good (93% and 86%, respectively).

Diffuse large B-cell lymphoma

There were five cases of DLBCL constituting 1% of all MBNHL cases. Only one case expressed CD5. Newer WHO classification defines a separate entity of CD5 positive DLBCL [3,45,55].

B NHL, unclassifiable

There were 15 cases of MBNHL (4%) which were not classifiable into any of the subtypes and were labeled as B NHL unclassifiable. Morphological and immunophenotypic features did not fit into any of the defined WHO categories and these cases didn't have a tissue biopsy for further confirmation.

There were a few drawbacks of this study. We did three color immunophenotyping with FSC/SSC gating. CD19 gating was done in very few selected cases. We did 13–20 antibodies per case (mean = 15) and our panel is more B cell centric with only two T-cell markers (CD3 and CD5). CD4 and CD8 were done in those selected cases only where a suspicion of T cell lymphoma was there. CD43 is a popular

Table VII. Individual marker expression in various subtypes of MBNHL.

	CD5 (%)	CD10 (%)	CD19 (%)	CD23 (%)	CD20 (%)	CD22 (%)	FMC7 (%)	CD79b (%)	Smlg (%)	IgM (%)	CD38 (%)	CD11 (%)c	CD103 (%)	CD25 (%)	K (%)	L (%)
CLL (N = 243)	90	0	100	95	89	50	9	26	82	48	34	75	0	0	56	44
CLL/PLL (N = 5)	80	0	100	100	100	80	40	60	100	100	60	ND	ND	ND	80	20
FL (N = 30)	10	93	100	43	93	54	80	87	100	78	55	ND	ND	ND	60	40
MCL (N = 20)	95	0	100	0	94	61	50	70	88	86	60	33	0	0	55	45
SMZL (N = 18)	11	0	100	33	100	100	72	72	100	100	18	50	0	0	78	22
HCL (N = 18)	39	0	100	6	100	67	72	61	93	64	13	100	100	78	39	61
DLBCL (N = 5)	20	60	100	20	100	20	100	80	100	80	80	ND	ND	ND	100	–
B–NHL unclassifiable (N = 15)	33	0	100	40	93	73	73	67	80	40	0	0	0	0	87	13

CLL, chronic lymphocytic leukemia; CLL/PLL, prolymphocytic leukemia; FL, follicular lymphoma; MCL, mantle cell lymphoma; SMZL, splenic marginal zone lymphoma; HCL, hairy cell leukemia; DLBCL, diffuse large B-cell lymphoma; MBNHL, mature B-cell non Hodgkin lymphoma.

marker, however was not done in our study [5,6]. Molecular genetics was available in selected few cases. We did not include staging BM for FCIP. Cases of BL and plasma cell dyscrasia were excluded from the analysis. Correlation with complete blood counts, clinical and treatment follow up was not done.

Conclusion

Lymphoma diagnosis is a multi-parameter approach. Many B-cell lymphomas cannot be fully sub classified by FCIP alone as no singular disease entity-specific antigen expressed on the cell surface has been identified. However, if the results of FCIP are critically evaluated and information regarding both the staining intensity and the presence or absence of certain antigens is recorded, they can provide useful information and serve as a guide to determine which cases require further tissue procurement or ancillary genetic studies. Understanding of intensities of different antibodies and of the fluorochromes used for conjugation is important. CD5-FITC combination produces a weak intensity and this could lead to false interpretation of results and reporting of CD5 negative CLL. Moreover there are exceptions to the rules as MCL have been reported to express CD23 [56]. 2006 Bethesda international consensus guidelines define an extensive reagent panel suitable for both AL and MBNHL [57]. Indian Guidelines, however, recommend a minimal primary panel for evaluating mature lymphoid neoplasms including CD19, CD5, CD23, CD10, FMC7, CD20, CD3, kappa and lambda [58] followed by a more comprehensive panel, if required, including CD38, CD138, CD43, CD56, CD16, CD11c, CD25 and CD103. This panel hopefully brings about uniformity and comparability in reporting of hematolymphoid malignancies and bridges the divide between low-cost reporting and an accurate diagnosis. We could further sub-classify 92% of our MBNHL cases based on above panel (in association with biopsy material). Clinical and morphological details should be taken into consideration for deciding the primary panel. CD23+FMC7 – in a CD5+MBNHL is highly suggestive of CLL. Additional markers like light chain restriction (or SmIg) on FCIP, and cyclin D1 on tissue specimen are helpful. Whether addition of CD79b is warranted, or cost effective, is not as clear because there was very little correlation between CD79b and FMC7 staining patterns. CD23 was commonly expressed in CLL and FL, while was uncommon in SMZL and HCL and absent in MCL. High discordance rate seen in SMZL could be attributed to unavailability of any definitive diagnostic criteria.

Declaration of interest: The authors report no conflicts of interest. The authors alone are responsible for the content and writing of the paper.

References

1. Chan JKC, Banks PM, Cleary ML, et al. A revised European-American classification of lymphoid neoplasms proposed by the international lymphoma study group: a summary version. *Am J Clin Pathol* 1995;103:543–560.
2. Morse EE, Yamase HT, Greenberg BR, et al. The role of flow cytometry in the diagnosis of lymphomas: a critical analysis. *Ann Clin Lab Sci* 1994;24:6–11.
3. Swedlow SH, Campo E, Harris NL, et al., editors. WHO Classification of Tumors of Hematopoietic and Lymphoid Tissues. Lyon: IARC; 2008.
4. Morice WG, Kurtin PJ, Hodnefield JM, et al. Predictive value of blood and bone marrow flow cytometry in B-cell lymphoma classification: comparative analysis of flow cytometry and tissue biopsy in 252 patients. *Mayo Clin Proc* 2008;83:776–785.
5. Matutes E, Owusu-Ankomah K, Morilla R, et al. The immunological profile of B-cell disorders and proposal of a scoring system for the diagnosis of CLL. *Leukemia* 1994;8:1640–1645.
6. Craig FE, Foon KA. Flow cytometric immunophenotyping for hematologic neoplasms. *Blood* 2008;111:3941–3967.
7. Garcia DP, Rooney MT, Ahmad E, et al. Diagnostic usefulness of CD23 and FMC-7 antigen expression patterns in B-cell lymphoma classification. *Am J Clin Pathol* 2001;115:258–265.
8. Babusikova O, Tomova A, Kusenda J, et al. Flow cytometry of peripheral blood and bone marrow cells from patients with hairy cell leukemia: phenotype of hairy cells, lymphocyte subsets and detection of minimal residual disease after treatment. *Neoplasma* 2001;48:350–357.
9. Xu Y, McKenna RW, Kroft SH. Assessment of CD10 in the diagnosis of small B-cell lymphomas: a multiparameter flow cytometric study. *Am J Clin Pathol* 2002;117:291–300.
10. Foucar K, McKenna RW, Frizzera G, et al. Bone marrow and blood involvement by lymphoma in relationship to the Lukes-Collins classification. *Cancer* 1982;49:888–897.
11. Onciu M, Berrak SG, Medeiros LJ, et al. Discrepancies in the immunophenotype of lymphoma cells in samples obtained simultaneously from different anatomic sites. *Am J Clin Pathol* 2002;117:644–650.
12. Hanson CA, Kurtin PJ, Katzmann JA, et al. Staging of B-cell malignant lymphoma immunophenotypic analysis of peripheral blood and bone marrow in the staging of B-cell malignant lymphoma. *Blood* 1999;94:3889–3896.
13. Dogan A. Modern histological classification of low grade B-cell lymphomas. *Best Pract Res Clin Haematol* 2005;18:11–26.
14. Kaleem Z, White G, Vollmer RT. Critical Analysis and Diagnostic Usefulness of Limited Immunophenotyping of B-Cell Non-Hodgkin Lymphomas by Flow Cytometry. *Am J Clin Pathol* 2001;115:136–142.
15. Pallesen G, Madsen M, Pedersen BB. B-prolymphocytic leukaemia—a mantle zone lymphoma? *Scand J Haematol* 1979;22:407–416.
16. Neilson JR, Fegan CD, Milligan DW. Mantle cell leukemia? *Br J Haematol* 1996;93:494–495.
17. Dascalescu C, Gressin R, Callana M, et al. t(11;14)(q13;q32): chronic lymphocytic leukaemia or mantle cell leukaemia? *Br J Haematol* 1996;95:570–576.

18. Ginaldi L, Martinis MD, Matutes E, et al. Levels of expression of CD19 and CD20 in chronic B cell leukaemias. *J Clin Pathol* 1998;51:364–369.
19. Kurec AS, Threatte GA, Gottlieb AJ, et al. Immunophenotypic subclassification of chronic lymphocytic leukemia (CLL). *Br J Haematol* 1992;81:45–51.
20. Baldini L, Cro L, Corteleszi A, et al. Immunophenotypes in “classical” B-cell chronic lymphocytic leukemia. Correlation with normal cellular counterpart and clinical findings. *Cancer* 1990;66:1738–1742.
21. Monaghan SA, Peterson LC, James C, et al. Pan B-cell markers are not redundant in analysis of chronic lymphocytic leukemia (CLL). *Cytometry B Clin Cytom* 2003;56B:30–42.
22. Delgado J, Matutes E, Morilla AM, et al. Diagnostic significance of CD20 and FMC7 expression in B-Cell disorders. *Am J Clin Pathol* 2003;120:754–759.
23. Huang JC, Finn W, Goolsby C, et al. CD5- negative B-cell leukemias are rarely classifiable as chronic lymphocytic leukemia. *Am J Clin Pathol* 1999;111:123–130.
24. Shapiro J, Miller M, Pohlman B, et al. CD5-negative B-cell lymphoproliferative disorders presenting in blood and bone marrow. A clinicopathologic study of 40 patients. *Am J Clin Pathol* 1999;111:477–487.
25. Batata A, Shen B. Immunophenotyping of subtypes of B-chronic (mature) lymphoid leukemia. A study of 242 cases. *Cancer* 1992;70:2436–2443.
26. Geisler C, Larsen J, Hansen N, et al. Prognostic importance of flow cytometric immunophenotyping of 540 consecutive patients with B cell chronic lymphocytic leukemia. *Blood* 1991;78:1795–1802.
27. Maloum K, Magnac D, Pritsch O, et al. Analysis of VH gene expression in CD5+ and CD5 – B-cell chronic lymphocytic leukemia. *Blood* 1995;86:3883–3889.
28. Kurec A, Threatte G, Gottlieb A, et al. Immunophenotypic subclassification of chronic lymphocytic leukemia (CLL). *Br J Haematol* 1992;81:45–51.
29. Matutes E, Oscier D, Garcia-Marco J, et al. Trisomy 12 defines a group of CLL with atypical morphology: correlation between cytogenetic, clinical, and laboratory features in 544 patients. *Br J Haematol* 1996;92:382–388.
30. De Rossi G, Mauro F, Lo Coco F, et al. CD5-lymphocytosis mimicking typical B-chronic lymphocytic leukemia: description of 26 cases. *Nouv Rev Fr Hematol* 1993;35:451–455.
31. Salomon-Nguyen F, Valensi F, Merle-Beral H, et al. A scoring system for classification of CD5– B-CLL versus CD5+ B-CLL and B-PLL. *Leuk Lymphoma* 1995;16:445–450.
32. Sheikh SS, Kallakury BVS, Al-Kuraya KA, et al. CD5-negative, CD10-negative small B-cell leukemia: variant of chronic lymphocytic leukemia or a distinct entity? *Am J Hematol* 2002;71:306–310.
33. Weisenburger DD, Duggan MJ, Perry DA, et al. Non-Hodgkin’s lymphomas of mantle zone origin. *Pathol Annu* 1991;26:139–158.
34. Bookman MA, Lardelli P, Jaffe ES, et al. Lymphocytic lymphoma of intermediate differentiation: morphologic, immunophenotypic, and prognostic factors. *J Natl Cancer Inst* 1990;82:742–748.
35. Dorfman DM, Pinkus GS. Distinction between small lymphocytic and mantle cell lymphoma by immunoreactivity for CD23. *Mod Pathol* 1994;7:326–331.
36. Kilo MN, Dorfman DM. The utility of flow cytometric immunophenotypic analysis in the distinction of small lymphocytic lymphoma/chronic lymphocytic leukemia from mantle cell lymphoma. *Am J Clin Pathol* 1996;105:451–457.
37. Kaptain S, Zukerberg LR, Ferry JA, et al. Bcl-1/cyclinD1+ CD5-mantle cell lymphoma [abstract]. *Mod Pathol* 1998;11:133a.
38. Bell ND, King JA, Kusyck C, et al. CD5 negative diffuse mantle cell lymphoma with splenomegaly and bone marrow involvement. *South Med J* 1998;91:584–587.
39. Liu Z, Dong HY, Gorczyca W, et al. CD5– mantle cell lymphoma. *Am J Clin Pathol* 2002;118:216–224.
40. Mann RB. Follicular lymphomas. In: Jaffe ES, editor. *Surgical Pathology of the Lymph Node and Related Organs*, 2nd edn. Philadelphia, PA: Saunders; 1995. pp 252–282.
41. Tiesinga JJ, Wu D, Inghirami G. CD5+ follicular lymphoma. Immunophenotyping detects a unique subset of “floral” follicular lymphoma. *Am J Clin Pathol* 2000;114:912–921.
42. Berekman CL, Aguilera NSI, Abbondanzo SL. Low-grade B-cell lymphoma with coexpression of both CD5 and CD10. A report of 3 cases. *Arch Pathol Lab Med* 2001;125:951–953.
43. Barry TS, Jaffe ES, Kingma DW, et al. CD5+ follicular lymphoma. A clinicopathologic study of three cases. *Am J Clin Pathol* 2002;118:589–598.
44. Dong HY, Gorczyca W, Liu Z, et al. B-cell lymphomas with coexpression of CD5 and CD10. *Am J Clin Pathol* 2003;119:218–230.
45. Manazza AD, Bonello L, Pagano M, et al. Follicular origin of a subset of CD5+ diffuse large B-cell lymphomas. *Am J Clin Pathol* 2005;124:182–190.
46. Ree HJ, Yang WI, Kim CW, et al. Coexpression of Bcl-6 and CD10 in diffuse large B-cell lymphomas: significance of Bcl-6 expression patterns in identifying germinal center B-cell lymphoma. *Hum Pathol* 2001;32:954–962.
47. Ott G, Katzenberger T, Lohr A, et al. Cytomorphologic, immunohistochemical, and cytogenetic profiles of follicular lymphoma: 2 types of follicular lymphoma grade 3. *Blood* 2002;99:3806–3812.
48. Esho C, Perkins S, Kampalath B, et al. Decreased CD10 expression in grade III and in interfollicular infiltrates of follicular lymphomas. *Am J Clin Pathol* 2001;115:862–867.
49. Guo Y, Karube K, Kawano R, et al. Low-grade follicular lymphoma with t(14;18) presents a homogeneous disease entity otherwise the rest comprises minor groups of heterogeneous disease entities with Bcl2 amplification, Bcl6 translocation or other gene aberrances. *Leukemia* 2005;19:1058–1063.
50. Bosga-Bouwer AG, van den Berg A, Haralambieva E, et al. Molecular, cytogenetic, and immunophenotypic characterization of follicular lymphoma grade 3B; a separate entity or part of the spectrum of diffuse large B-cell lymphoma or follicular lymphoma? *Hum Pathol* 2006;37:528–533.
51. Banks PM, Isaacson PG. MALT lymphomas in 1997: where do we stand? *Am J Clin Pathol* 1999;111(suppl 1):S75–S83.
52. Matutes E, Morilla R, Owusu-Ankomah K, et al. The immunophenotype of splenic lymphoma with villous lymphocytes and its relevance to the differential diagnosis with other B-cell disorders. *Blood* 1994;83:1558–1562.
53. Stetler-Stevenson M, Medeiros LJ, Jaffe ES. Immunophenotypic methods and findings in the diagnosis of lymphoproliferative diseases. In: Jaffe ES, editor. *Surgical Pathology of the Lymph Node and Related Organs*, 2nd edn. Philadelphia, PA: Saunders; 1995. pp 22–57.
54. Carey JL, Hanson CA. Flow cytometric analysis of leukemia and lymphoma. In: Keren DF, Hanson CA, Hurtubise PE, editors. *Flow cytometry and clinical diagnosis*. Chicago, IL: ASCP Press; 1994. pp. 197–308.
55. Vassallo J, Bousquet M, Quelen C, et al. CD5-positive diffuse large B cell lymphoma arising from a CD5-positive follicular lymphoma. *J Clin Pathol* 2007;60:573–575.
56. Schlette E, Fu K, Medeiros LJ. CD23 expression in mantle cell lymphoma: clinicopathologic features of 18 cases. *Am J Clin Pathol* 2003;120:760–766.

57. Wood BL, Arroz M, Barnett D, et al. Bethesda international consensus recommendations on the immunophenotypic analysis of hematolymphoid neoplasia by flow cytometry: optimal reagents and reporting for the flow cytometric diagnosis of hematopoietic neoplasia. *Cytometry* 2007;72:S14–S22.
58. Gujral S, Subramanian PG, Patkar N, et al. Report of proceedings of the national meeting on “Guidelines for Immunophenotyping of Hematolymphoid Neoplasms by Flow Cytometry”. *Indian J Pathol Microbiol* 2008;51:161–166.