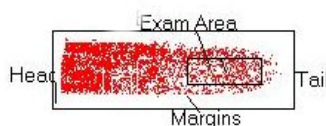




## Haemato-Oncopathology PB Smear: An Experience

With over 40 yrs of experience in Lab. Medicine, I wish to share my experiences with all, (some of you may have a similar experience) particularly in haemato-oncopathology. These are:

1. Examination of peripheral blood smear is single most important examination in Lab. Medicine and time spent is well rewarded. PBS should always be prepared from direct (without addition of anticoagulants) blood and it should have a head, tail and clear margins and best part to be examined is near the tail end as shown in the picture. Here the morphology of cells is absolutely clear and details can be better perceived.



2. In case of cytopenia always look for adequacy of platelets and immaturity of WBC as we are faced with increasing no. of leukemias in aleukemic phase at the time of initial diagnosis.

3. Occasional immature cells may be present in infants, so differentiate between normal and neoplastic immature cells. And also look for other parameters like associated anemia and thrombocytopenia and give guarded opinion with advice to follow-up in infants.

4. In megaloblastic anaemias presence of some atypical nucleated RBC (Megaloblastoid cell) and atypical WBC, may point to preleukemia (MDS), so advice accordingly for marrow study.

5. Even after recognizing few or occasional immature blast cells, examine many more cells, as there is a wide spectrum of morphologically aberrant cells to enrich your experience. Their details of morphology would help in recognizing early phase of leukemia / preleukemias.

6. Sometimes azurophilic granules may hardly be visible in myeloid cells (particularly in promyelo, myelo and metamyelocytes) in cases of CML undergoing chemotherapy and so the differential count may create problems. MGG stain may be little more helpful in such cases compared to Leishman.

7. Hypogranularity or even nongranularity of Promyelos in some cases of APML (microgranular type) may create problems, especially when their nucleus is convoluted and atypical giving an impression of monocytoïd morphology, here MPO stain is of great help being strongly peroxidase positive.

8. Differentiation of some Ac. Leukemias with highly atypical cells may be difficult sometimes, despite detailed morphology and cytochemical stains (MPO, PAS and NSE) all of which are negative. Here such leukemias can be labeled as Ac. Undifferentiated Leukemia (AUL) and advised for Immunophenotyping.

9. Diagnosis of Chronic Leukemias in early phases may be difficult. LAP stain with decreased LAP (less than 50 score) can be of help in CML-CP and absolute Lymphocytosis (above 15000/cmm) with presence of some degenerating Lymphocytes (Gumperts shadows) in PB smear can be of help in early phases of CLL.

10. Counterstain by saffranin in MPO stain gives better results for peroxidase positivity compared to Leishman or Giemsa counter stain.

11. Nucleolar morphology of blast cells is better perceived in MPO stain counterstained by Leishman or Giemsa .

**Dr. G.D. Mody, MD (Path & Bact) 1962**

Haematopathologist

Getwell Clinic

Jaipur

Email: [gdmody@eth.net](mailto:gdmody@eth.net)