

Title:

A Rare Variant of Metaplastic Carcinoma (Carcinosarcoma) High Grade of the Breast displaying IDC , Osteogenic Sarcoma , Squamous Cell Carcinoma , and Lymphovascular invasion

Case

Metaplastic Carcinoma of Breast

60 years old Female

Left Breast Mass

Histopathology

Metaplastic Carcinoma of Breast

Carcinosarcoma of Breast

High Grade

Components of the tumor

Infiltrating Duct Carcinoma

Lymphocytic infiltration

Squamous Cell Carcinoma

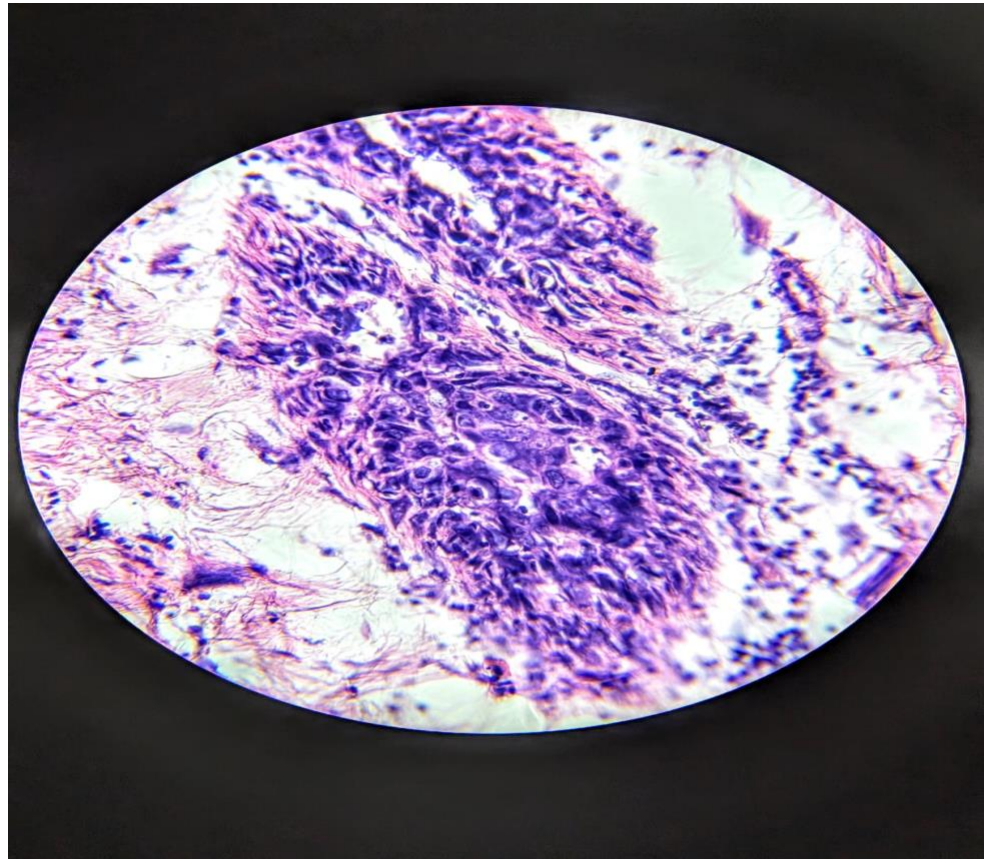
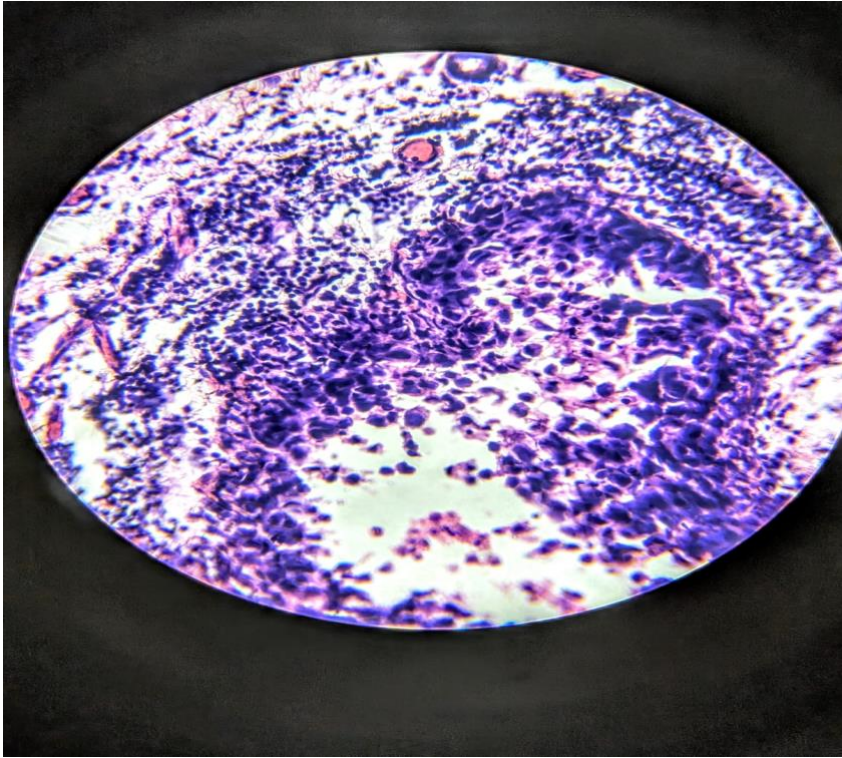
Osteogenic Sarcoma

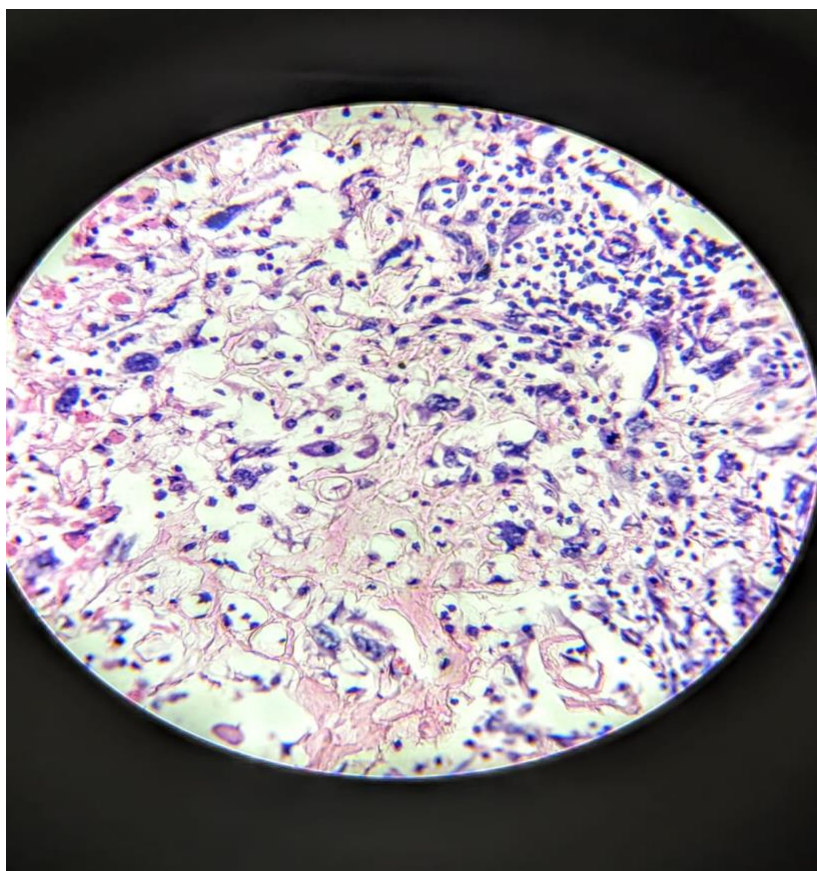
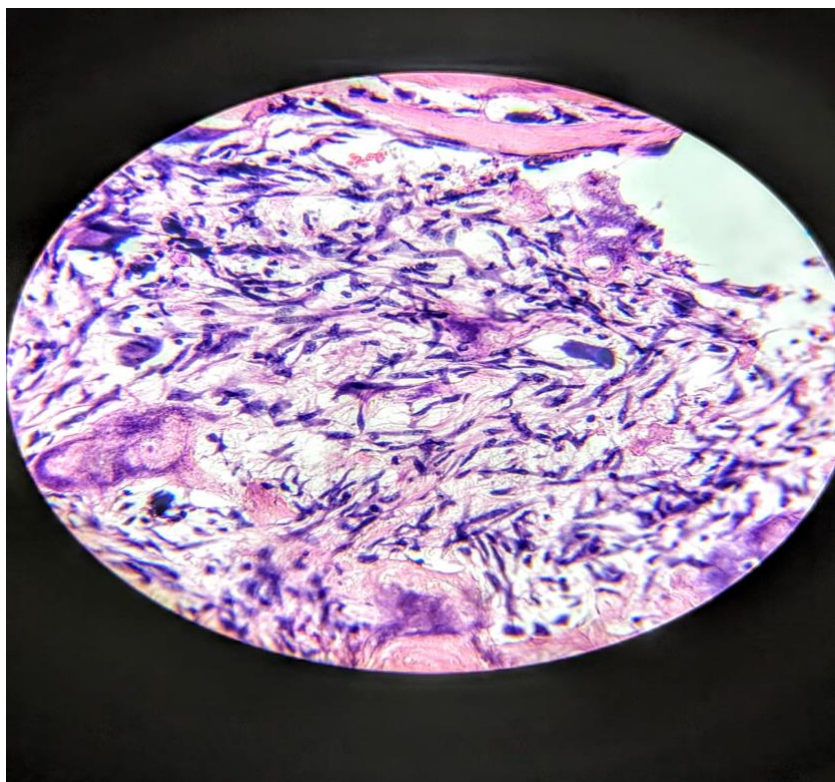
Lymphovascular invasion

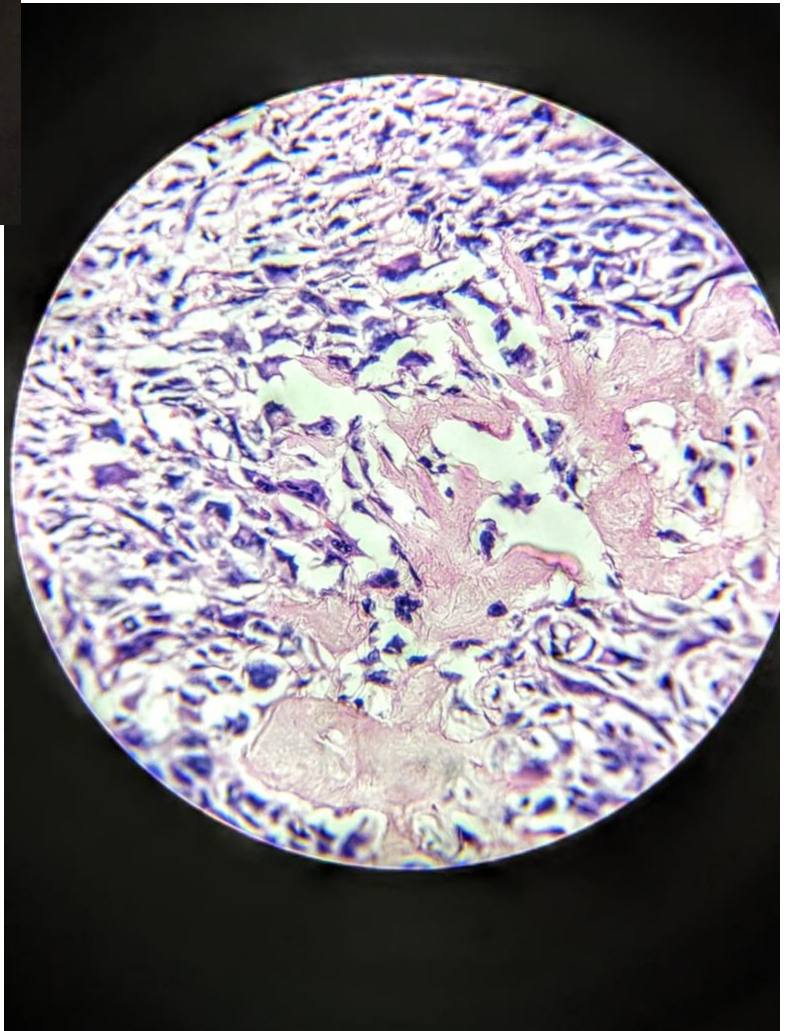
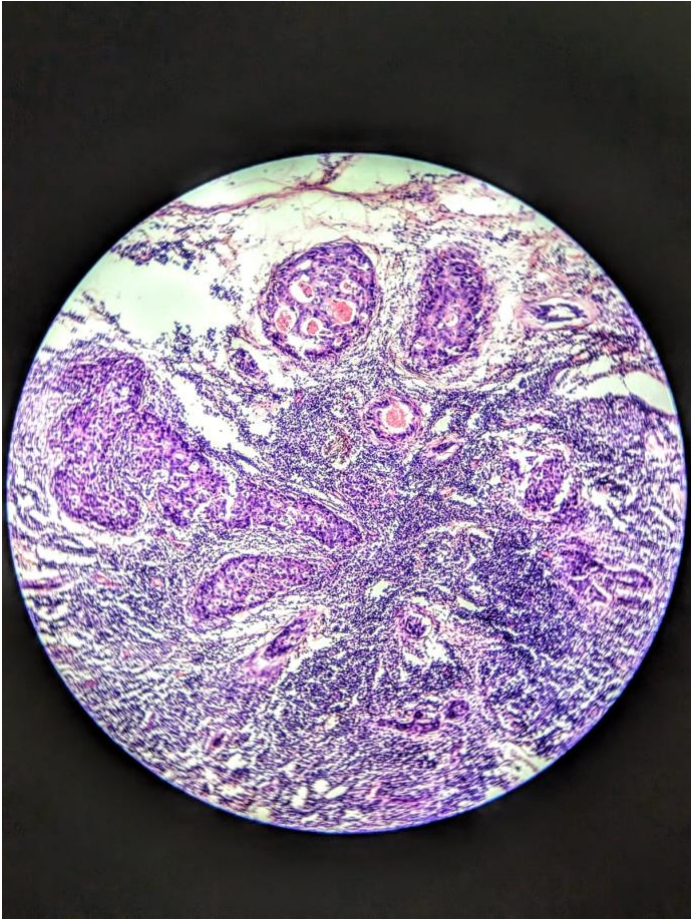
Surgical margins positive with tumor infiltration

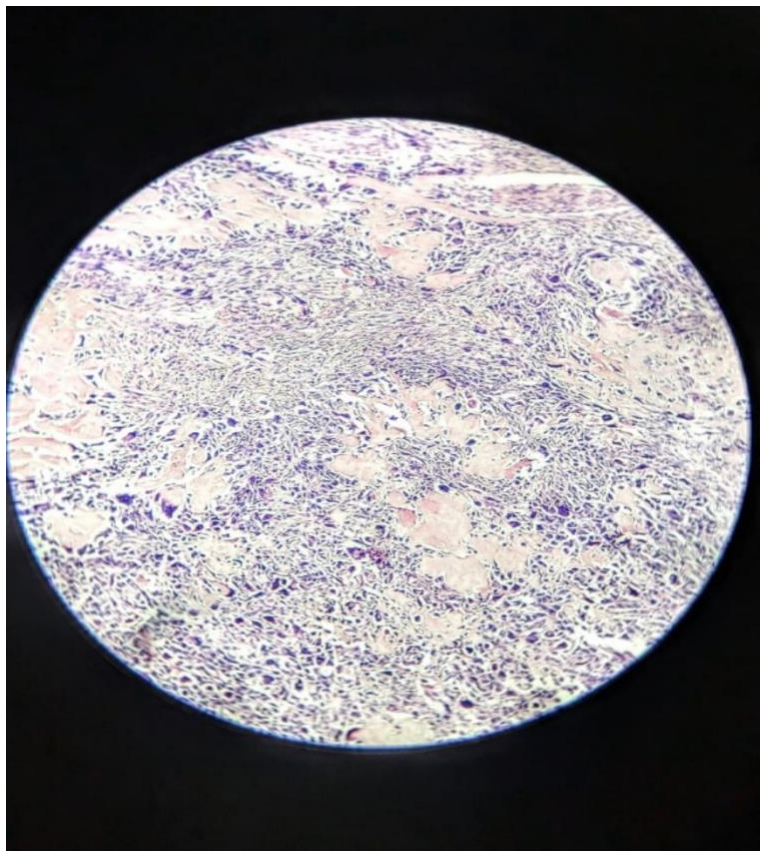
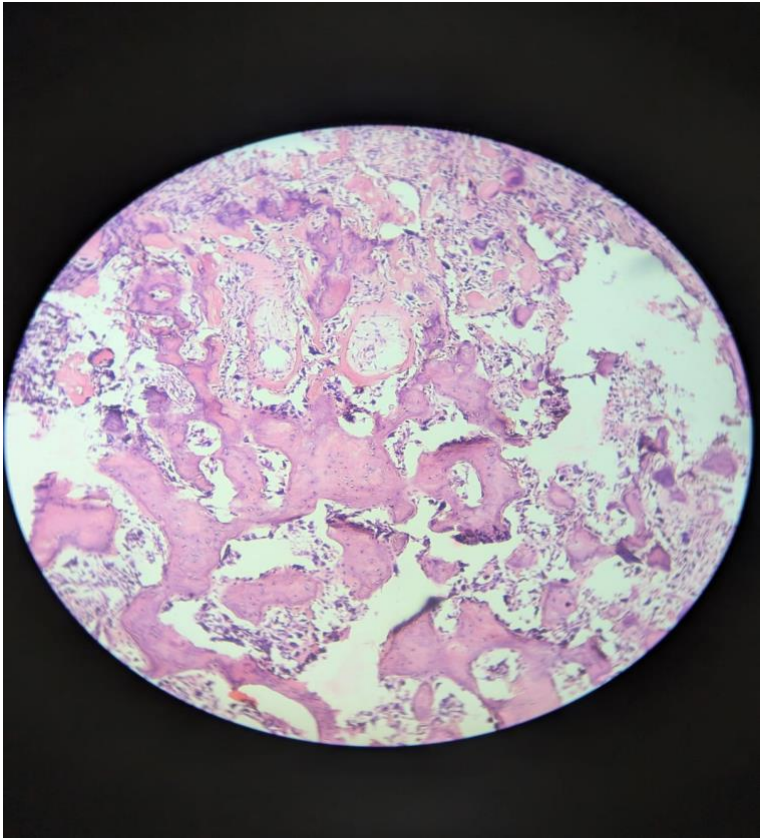
High Grade

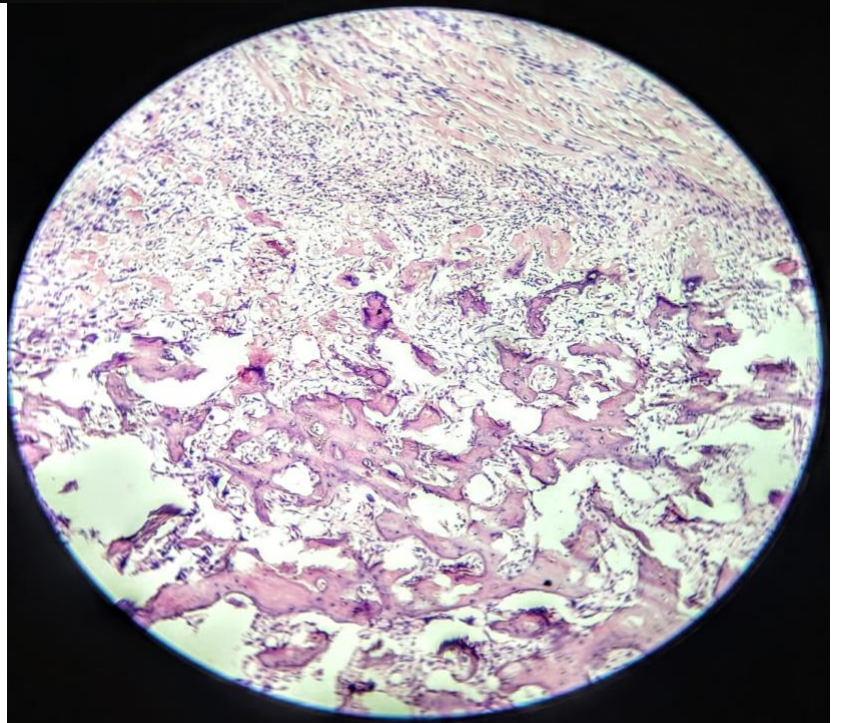
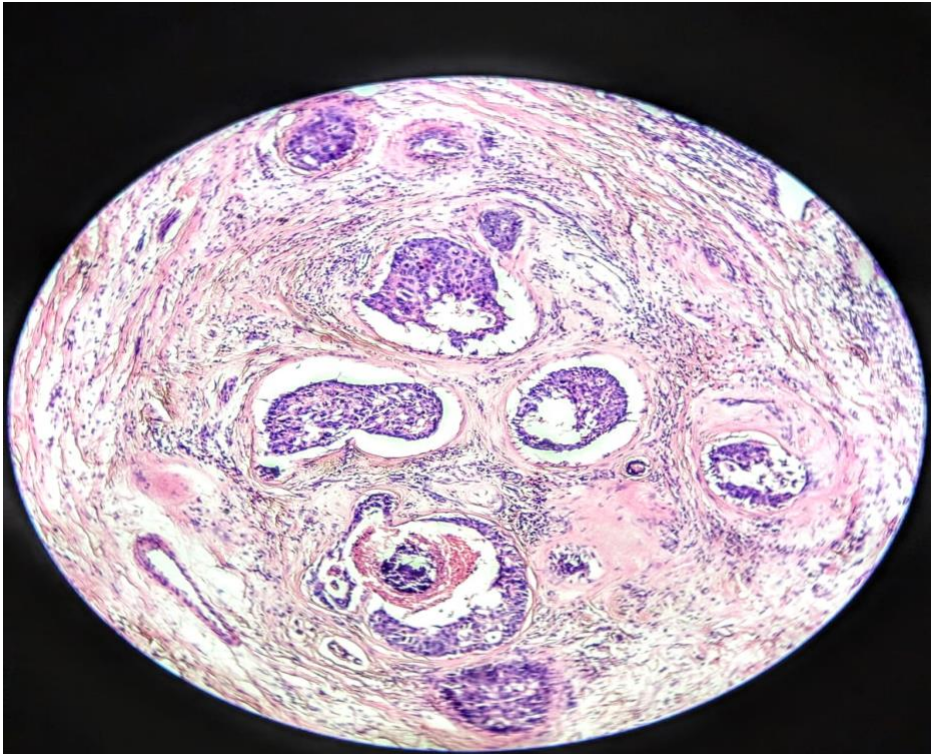
Triple Negative

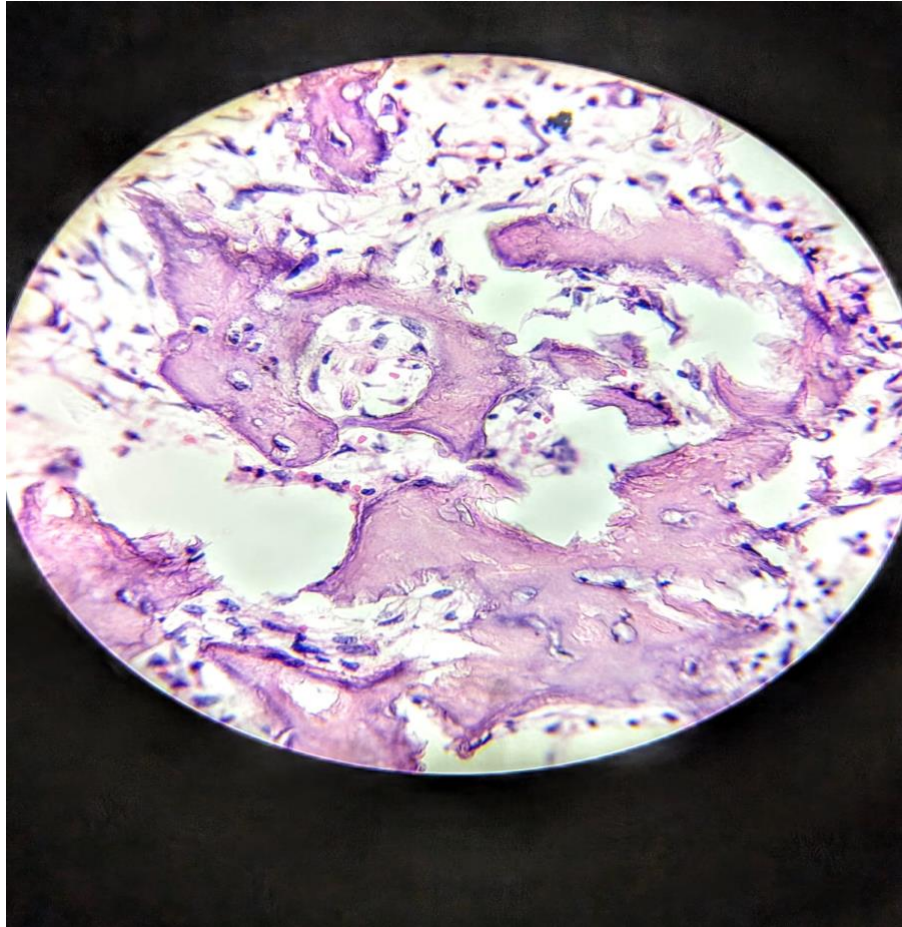












By

Dr RG. Wiseman Pinto

Professor of Pathology

Former HOD

Former Dean Goa University

President Asian Society of Cytopathology

Former Executive Council Member ,Academic Council Member and
Court Goa University

Indias Rep at IAC International Academy of Cytology, EFCS
European Federation of Cytology Societies

